

LETTER TO THE EDITOR

Open Access



Combined greater auricular and lesser occipital nerve block in cochlear implant for an ear-to-ear smile

Heena Garg¹, Debesh Bhoi^{1*}  and Kapil Sikka²

To the Editor

Cochlear implant is commonly performed for irreversible hearing loss in the paediatric age group to facilitate their early rehabilitation (Vincenti et al. 2014) The surgery itself is associated with moderate to severe pain and a high incidence of postoperative nausea vomiting (PONV) (Piraudeau and Mendonca 2019) Pain in this population subgroup is difficult to treat due to the inability of these children to express pain and assess the response to analgesics. Furthermore, the use of opioids to treat pain can exacerbate the PONV in this susceptible surgical subgroup which can lead to delayed recovery. A pre-emptive block can be highly effective to decrease the incidence of pain and reduce the postoperative opioid consumption. The use of greater auricular nerve (GAN) block has been defined in the paediatric age group undergoing tympanomastoid surgery (Santhanam et al. 2002) A concomitant lesser occipital nerve (LON) block has been described for cochlear implantation in the elderly age group under local anaesthesia (Connors et al. 2021) We combined both the blocks in this case series of two

children, 2–3 years male, who presented for cochlear implant surgery to our institute after informed consent from the parents.

Anaesthesia was induced with fentanyl 2 µg/kg, propofol in titrated doses and atracurium 0.5 mg/kg. The trachea was intubated with appropriate-sized cuffed tube. After head positioning, under all aseptic precautions, ultrasound-guided GAN and LON block were given using a 5-cm echogenic needle using a hockey stick linear probe (6–13 MHz) (Sonosite®). The probe was placed over the sternocleidomastoid muscle at its midpoint. Both the nerves were blocked in the same approach from medial to lateral direction using 1 ml 0.375% ropivacaine (Fig. 1). The patients did not show any response to skin incision. Additional bolus of 0.5 µg/kg fentanyl was only needed during mastoid drilling and no further opioid was used intraoperatively and postoperatively. I.V. paracetamol was administered (15 mg/kg) at the end of surgery and ibugesic (ibuprofen + paracetamol) syrup, when required was advised for postoperative analgesia. Both the children were comfortable postoperatively and required analgesia only after 12 h. However, the FLACC

This manuscript was presented as a poster in AACA 2022, Korea.

*Correspondence:

Debesh Bhoi
debeshbhoi@gmail.com

¹ Department of Anaesthesiology, Pain Medicine and Critical Care, All India Institute of Medical Sciences, New Delhi, India

² Department of Otolaryngology & Head and Neck Surgery, All India Institute of Medical Sciences, New Delhi, India



© The Author(s) 2023. **Open Access** This article is licensed under a Creative Commons Attribution 4.0 International License, which permits use, sharing, adaptation, distribution and reproduction in any medium or format, as long as you give appropriate credit to the original author(s) and the source, provide a link to the Creative Commons licence, and indicate if changes were made. The images or other third party material in this article are included in the article's Creative Commons licence, unless indicated otherwise in a credit line to the material. If material is not included in the article's Creative Commons licence and your intended use is not permitted by statutory regulation or exceeds the permitted use, you will need to obtain permission directly from the copyright holder. To view a copy of this licence, visit <http://creativecommons.org/licenses/by/4.0/>.

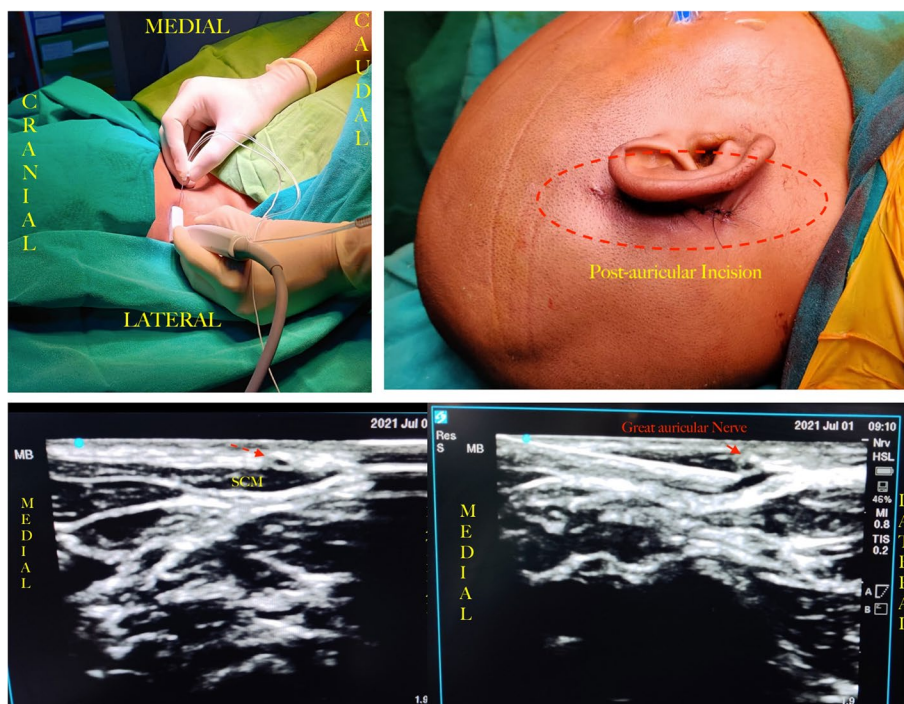


Fig. 1 Figure showing the direction of needle entry and the sonoanatomy of greater auricular and lesser occipital nerve

(pain) scale was less than 4 till 24 h follow-up (Merkel et al. 2002).

Therefore, a combined greater auricular nerve block and lesser occipital nerve block may provide effective analgesia in paediatric patients undergoing cochlear implant surgery.

Abbreviations

PONV	Postoperative nausea vomiting
GAN	Greater auricular nerve
LON	Lesser occipital nerve
I.V.	Intravenous
FLACC	Face, Legs, Activity, Cry, Consolability scale

Acknowledgements

Not applicable

Authors' contributions

DB initiated the manuscript and collected the manuscript data. HG prepared the manuscript. KS was involved in overall design and execution of manuscript. All authors read and approved the final manuscript.

Funding

No source of funding.

Availability of data and materials

Data can be made available on request.

Declarations

Ethics approval and consent to participate

Ethics approval is given by Institutes Ethics Committee of All India Institute of Medical Sciences. Ref. No.: IEC-517/01.09.2023. The guardians of the children

were informed about the block and consent was taken for administration of block.

Consent for publication

Consent to publish was obtained from the parents. No information disclosing the identity of the patients has been included in the manuscript.

Competing interests

The authors declare that they have no competing interests.

Received: 2 January 2023 Accepted: 22 July 2023

Published online: 04 October 2023

References

- Connors JR, Deep NL, Huncke TK, Roland JT Jr (2021) Cochlear implantation under local anesthesia with conscious sedation in the elderly: first 100 cases. *Laryngoscope* 131:E946–E951
- Merkel S, Voepel-Lewis T, Malviya S (2002) Pain control: pain assessment in infants and young children: the FLACC scale. *Am J Nurs* 102(10):55–58
- Pairaudeau C, Mendonca C (2019) Anaesthesia for major middle ear surgery. *BJA Education* 19(5):136–143. <https://doi.org/10.1016/j.bjae.2019.01.006>
- Santhanam S, Sandra LB, Nancy MY et al (2002) Postoperative pain relief in children undergoing tympanomastoid surgery: is a regional block better than opioids? *Anesthesia Analgesia* 94(4):859–862. <https://doi.org/10.1097/0000539-200204000-00015>
- Vincenti V, Bacciu A, Guida M, Marra F, Bertoldi B, Bacciu S et al (2014) Pediatric cochlear implantation: an update. *Ital J Pediatr* 40(1):72

Publisher's Note

Springer Nature remains neutral with regard to jurisdictional claims in published maps and institutional affiliations.