

ORIGINAL ARTICLE

Open Access



Pre-emptive ultrasound-guided superior hypogastric plexus block in pelvic cancer surgeries: a randomized double-blinded study

Essam Mahran^{1*}  and Mohamed A. Wadod¹

Abstract

Background Superior hypogastric plexus is a retroperitoneal plexus that receives visceral sensation from pelvic viscera. Superior hypogastric plexus block (SHPB) was used for chronic pelvic pain and recently studied for postoperative pain. We examined the safety and efficacy of preemptive anterior US-guided SHPB to reduce postoperative morphine consumption. Thirty-six patients undergoing pelvic cancer surgery were randomly divided into two equal groups; group S in which patients received anterior US-guided SHPB immediately after induction of general anesthesia and before skin incision using 20 ml bupivacaine 0.5%, group C control group in which 20 ml normal saline was given by the same technique. Patients of both groups received morphine via PCA postoperative and followed for 24 h. In both groups, we measured the total morphine consumption, VAS, vital signs, and side effects.

Results Demographic data, duration, and type of surgery were comparable in both groups. Total 24 h morphine consumption in mg was significantly lower in group S (43.8 ± 2) than in group C (54.83 ± 2) with P value < 0.001 . VAS was significantly lower in group S in all time intervals from 2 till 24 h postoperative. Side effects were minimal with no significant difference between both groups.

Conclusion Preemptive US-guided SHPB is a relatively safe and effective method to reduce postoperative opioid demands after pelvic cancer surgeries.

Trial registration ClinicalTrials.gov NCT04732234 in 1–2–2021.

Keywords Preemptive, US guided, Superior hypogastric plexus block, Pelvic surgery

Background

Postoperative pain is a common surgical consequence with a variable severity as 18% of patients suffer extreme pain (Apfelbaum et al. 2003).

Intravenous opioids are commonly used as the standard method to treat postoperative pain (Benhamou et al. 2008). However, they have many side effects such as

vomiting, pruritus (itching), sedation (drowsiness), and patient concerns about addiction (Apfelbaum et al. 2003).

Preemptive analgesia involves the initiation of analgesia before surgical incision. It is thought that by initiating analgesic before surgical injury, it can reduce the intraoperative nociception to the central nervous system and therefore provide superior pain relief compared with giving the analgesic after incision (Kissin 2000; Dahl and Kehlet 2011).

Anatomically, the superior hypogastric plexus (SHP) is a retroperitoneal nervous plexus that is located bilaterally anterior to the lower third of the L5 and the upper third of the S1 vertebral bodies caudal to the bifurcation of the iliac vessels. The SHP contains visceral sympathetic nerve

*Correspondence:

Essam Mahran
essammahran66@yahoo.com

¹ Department of Anesthesiology & Pain Management, National Cancer Institute, Cairo University, Kasr Al Eini Street, Fom El Khalig, Cairo, Egypt

fibers and supplied also by branches of the aortic plexus and lumbar splanchnic nerve (Gofeld et al. 2018). It innervates the viscera of the pelvis, including the urinary bladder, ureters, sigmoid colon down to the anal canal, uterus, and upper vagina (Prithvi Raj and Erdine 2012). Accordingly, SHP destruction and presacral neurectomy was used for more than a century for treatment of pelvic pain (Le 1899) SHPB was first described by Plancarte et al. in 1990. SHP neurolysis was proved to be effective in treating chronic pelvic cancer pain (Plancarte et al. 1990).

The use of anterior ultrasound-guided superior hypogastric plexus neurolysis is a newer technique that was found effective in the treatment of gynecological pelvic cancer pain (Mishra et al. 2013).

Although SHPB was used primarily for chronic pelvic pain (Rocha et al. 2020), it was investigated also for postoperative analgesia after pelvic surgery (Binkert et al. 2015). SHPB was investigated to be performed surgically during total abdominal hysterectomy (Rapp et al. 2017) and during laparoscopic gynecological surgeries (De Silva et al. 2022).

The study hypothesis is that preemptive ultrasound-guided superior hypogastric plexus block reduces the need for analgesia and it is safe in pelvic cancer surgeries.

Our primary outcome was the total 24 h morphine consumption. Secondary outcomes were visual analogue scale (VAS) at 0–2–4–8 and 24 h postoperative, vital signs (HR and MBP), and side effects of both the technique and the used drugs (bupivacaine and morphine).

Methods

This study was conducted in National Cancer Institute, Cairo after obtaining institutional ethical committee board approval (IRB no: IRB0004025 on 22 June 2020) and clinical trial registration (NCT04732234). A written informed consent was obtained from each participant before the surgery. The study included 36 patients undergoing pelvic cancer surgeries between February 2021 till December 2022. Inclusion criteria were age 18–70 years, ASA II, III, patients undergoing pelvic surgeries, while exclusion criteria were patients, refusal, coagulopathy, and local infection at site of the block. Patients were randomized according to an online random number generator (computer-generated sequence). Concealment was achieved using sealed opaque envelopes. Upon arrival to the operating room, basic monitors were applied (electrocardiogram (ECG), non-invasive blood pressure, pulse oximetry, and capnography). Anesthesia was induced by propofol (2 mg/kg) and fentanyl (2 µg/kg). After induction of anesthesia, endotracheal intubation was facilitated by IV rocuronium (0.5 mg/kg). Anesthesia was maintained by sevoflurane (2%) and rocuronium (0.1 mg/

kg every 40 min). Both the patient and the anesthetist were blinded to which group the patient were allocated.

Ultrasound-guided technique (Mishra et al. 2013)

Bowel preparation was done, and urinary catheter was inserted to empty the bladder before surgery. The technique was done under complete aseptic conditions with the patient in supine position. A curved transducer 2–5 MHz of ultrasound machine (Sonosite, M-Turbo, USA) was placed 3–4 cm below umbilicus to identify the division of the abdominal aorta into the two common iliac arteries by placing the probe longitudinally, then the body of L5 lumbar vertebra was identified by rotating the transducer transversely. A 22-G, 15-cm Chiba needle was introduced in an out of plane technique, and advanced away from vascular structures (using Doppler mode) until bony contact with L5 vertebra. The needle then was withdrawn for 2 mm to avoid injection into the periosteum then injection was done. using ultrasound help the introduction of the needle through its path and show real-time injection of local anesthetic.

Patients were randomly allocated in this double-blinded study into two equal groups; group S (18 patients) in which ultrasound-guided SHPB is done using 20 ml Bupivacaine 0.5% before skin incision, group C (control group 18 patients) in which same the technique was done with injecting 20 ml normal saline 0.9% instead of bupivacaine. The spread of the injectate was better visualized as a hyperechoic drug cloud centripetally expanding from the echogenic tip of Chiba needle into the well-defined spaces in both sagittal and longitudinal images (Figs. 1 and 2). Patients of both groups received patient-controlled analgesia with continuous background infusion of morphine 40 mg/100 ml with addition of granisetron (Em-Ex[®], Amoun, Egypt) 4 mg/100 ml at a continuous infusion rate 4 ml/h with the ability to give a bolus of 2 ml (0.8 mg) morphine on demand and lockout interval 10 min.

Sample size determination

Based on a previous study done to assess the difference in opiate dose after SHPB the needed sample size for each group was 12 patients, with type I error 0.05 and power of study of 90% (Binkert et al. 2015). It was increased by 15% to adjust for non-parametric tests and 25% to compensate for lost follow-up, so the total calculated sample size was 36 patients (18 patients in each group). Sample size calculation was done by G* power Statistical package version 3.1.9.2.

Statistical analyses

Data was analyzed using SPSS win statistical package version 22. Numerical data was expressed as mean and

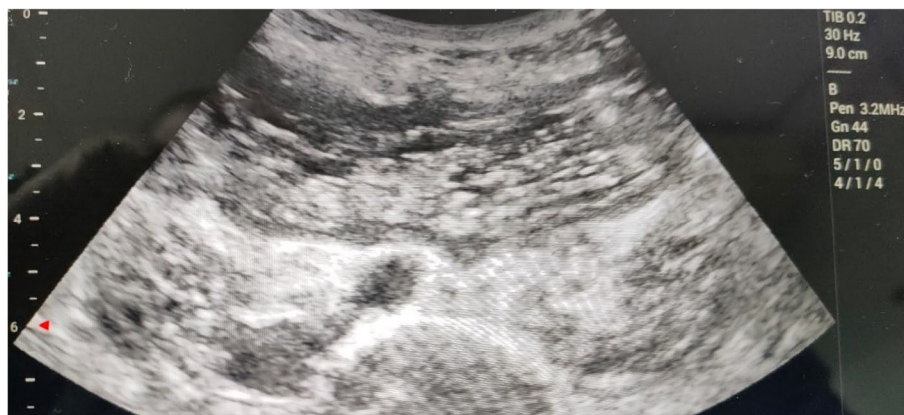

Fig. 1 SHPB anterior approach before injection

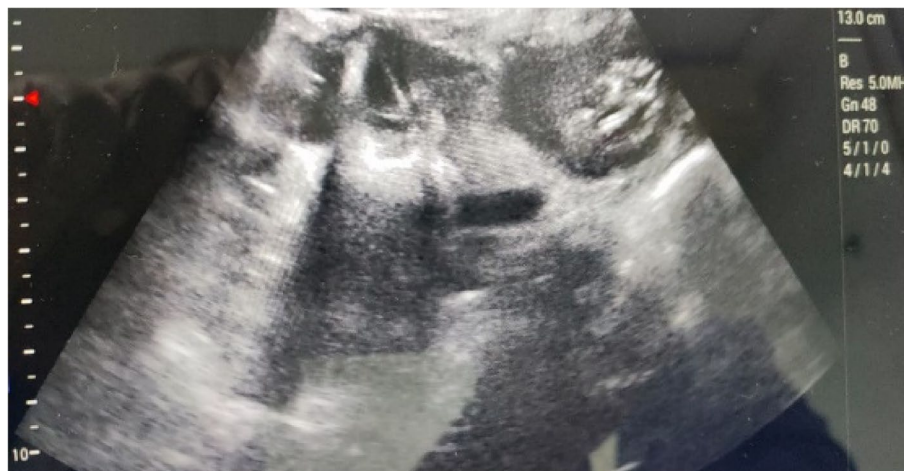

Fig. 2 SHPB anterior approach during injection

standard deviation (SD) or median and range as appropriate. Qualitative data was expressed as frequency and percentage. Testing for normality was done using Kolmogorov–Smirnov test and Shapiro–Wilk test. Chi-square (Fisher’s exact) test was used to examine the relation between qualitative variables as appropriate. For quantitative data, comparison between two groups was done using either Student’s *t* test or Mann–Whitney test (non-parametric *t* test) as appropriate. *p* value ≤ 0.05 was considered significant.

Results

Forty patients were assessed for eligibility. Four patients were excluded (2 patients not fulfilling inclusion criteria and 2 refused to participate). Thirty-six patients continued the study and randomly divided into the 2 groups (18 patients each group) as in the CONSORT diagram.

Demographic data (age, body mass index, and sex), duration of surgery and type of surgery were comparable in both groups with insignificant difference (Table 1). Total morphine consumption was significantly lower in group S than in group C with *P* value < 0.001 (Table 2). VAS was significantly lower in group S than in group C at 2 h, 4 h, and 8 h and 24 h (*P* value = 0.001, 0.002, 0.005, and 0.001 respectively) and was insignificantly different at baseline (0 h) as in Fig. 3.

Postoperative mean arterial blood pressure was significantly lower in group S than group C at 2 h and 4 h (*P* value = 0.001 and 0.005 respectively), and was insignificantly different at baseline, 8 h, and 24 h between both groups as in Fig. 4. However, these statistically significant data were clinically insignificant as they were in the clinically accepted range. Postoperative heart rate was significantly lower in group S than group C at 2 h, 4 h, and 8 h

Table 1 Demographic data of the studied group

		Group S (n = 18)	Group C (n = 18)	P value
Age (years)		51.33 ± 5.44	53.11 ± 4.60	0.297
BMI (kg/m ²)		24.56 ± 2.50	25.33 ± 2.77	0.382
Sex	Male	6 (27.8%)	10 (55.6%)	0.179
	Female	12 (66.7%)	8 (44.4%)	
Duration of surgery (min)		158.33 ± 22.03	162.22 ± 20.45	0.587
Type of surgery	Hysterectomy	8 (44.4%)	9 (50.0%)	0.792
	Cystectomy	10 (55.6%)	9 (50.0%)	

Data presented as mean ± SD or frequency (%), BMI Body mass index

Table 2 Total morphine consumption of the studied group

	Group S (n = 18)	Group C (n = 18)	P value
Total morphine consumption (mg)	43.83 ± 2.09	54.83 ± 2.12	0.001

Data presented as mean ± SD

(*P* value = 0.003, 0.001, 0.015 respectively), and was insignificantly different at baseline and 24 h between both groups as in Fig. 5. However, these differences were of no clinical significance.

Postoperative nausea and vomiting (PONV) occurred in 2 patients (11.1%) in group S and 2 patients (11.1%) in group C (*P* value = 1). No major complications were noticed in all cases of both groups; respiratory depression, local anesthetic toxicity, vascular, or bowel injury.

Discussion

SHPB was routinely done by fluoroscopy-guided bilateral posterior approach (Plancarte et al. 1997). Newer techniques were used like trans-discal and CT-guided approaches (Waldman et al. 1991; Cariati et al. 2002). The newer ultrasound-guided anterior approach minimizes the radiation exposure risks (Mishra et al. 2008; Mishra et al. 2013). The main concern of this technique is the potential injury to structures overlying the plexus such as common iliac arteries, bowel and bladder, and the risk of infection from bowel perforation. Preoperative bowel and bladder preparation, Trendelenburg position, and smaller size Chiba needle helped to avoid the visceral injury by collapsing the viscera away from the needle path. Avoidance of vessel injury by guidance and following negative aspiration of blood. The use of colored

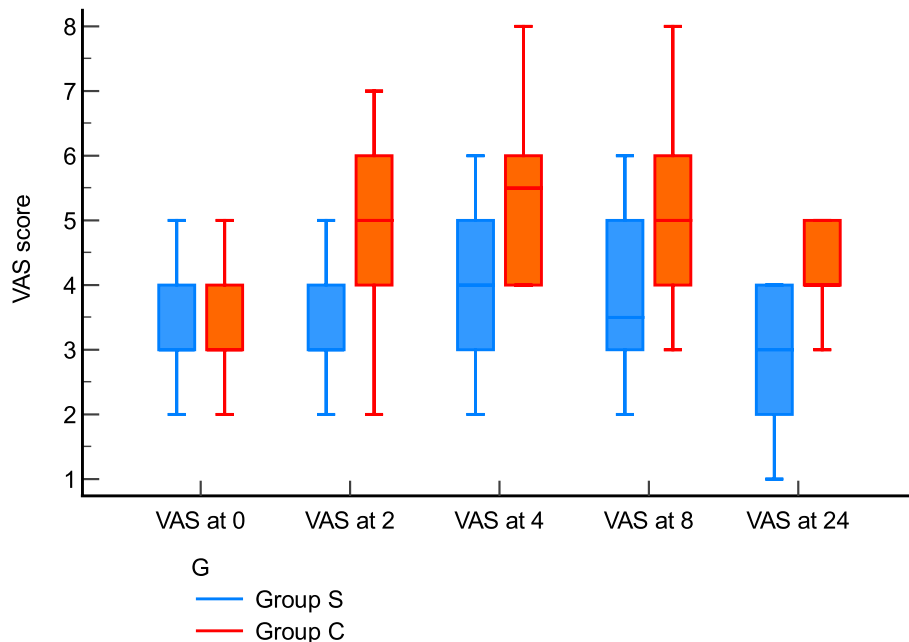


Fig. 3 VAS score between both groups

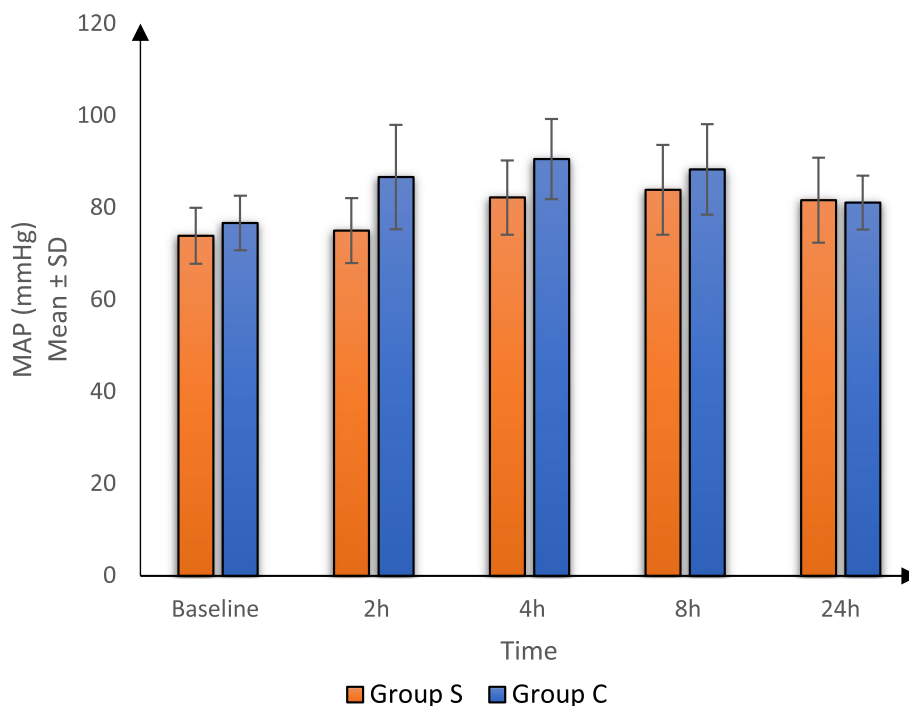


Fig. 4 Postoperative mean arterial blood pressure between both groups

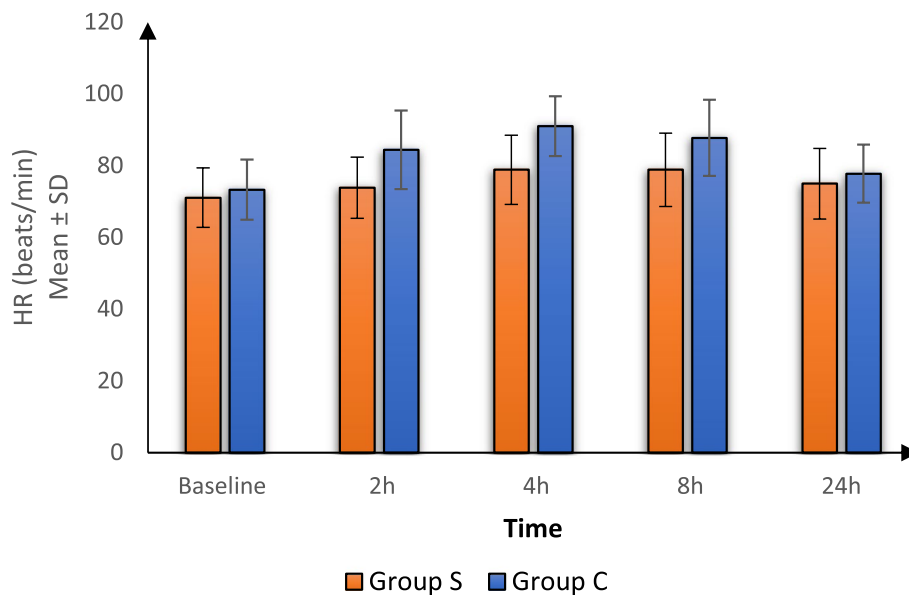


Fig. 5 Postoperative heart rate between both groups

doppler sonography helped to avoid the needle injury complications.

In the present study we studied the efficacy and safety of preemptive US-guided anterior approach of SHPB in pelvic surgery. We found that it markedly reduced the total 24 h morphine consumption with lower VAS score

at all time intervals starting from 2 h postoperative. Vital signs (HR and MBP) although showed some statistical significance but with no clinical significance.

Our primary outcome morphine consumption was less in SHPB group, and these results agreed with results of Rapp et al. after abdominal hysterectomy (Rapp

et al. 2017), De Silva et al. in minimally invasive robotic gynecological surgeries (Silva et al. 2022) and Peker et al. during cesarean section (Peker et al. 2021).

VAS was significantly reduced in our present study in SHBP group through all time intervals from 2 till 24 h. These results coincide with those of De Silva et al. (2022), Peker et al. (2021), and Aytuluke et al. (2019). They found improvement in VAS score with SHBP, however they measured the VAS score till 48 h postoperative.

Nausea and vomiting showed no difference between the two groups and these results are similar to those of Rapp et al. and Aytuluk et al. (Rapp et al. 2017; Aytuluk et al. 2019). Also, no major complications were reported like local anesthetic toxicity, bowel injury, and vascular injury. These results coincide with those of Mishra et al. (2013).

Postoperative pain has a visceral and a somatic component. SHPB is mainly used to control the visceral pain (Sindt and Brogan 2016). Accordingly, adding other nerve block techniques for somatic pain control (i.e., transversus abdominis plane block, ilioinguinal and iliohypogastric block) is recommended for more effective pain relief. In this regard, Carney et al. suggested transversus abdominis plane block as a method for postoperative pain relief in patients undergoing hysterectomy (Carney et al. 2008).

There were studies that investigated SHPB in the perioperative period despite still little in comparison with the studies investigating it in chronic pelvic pain. However, the intervention in these studies was done surgically either open or during laparoscopy in pelvic surgeries. In addition, in these studies the SHPB was performed after surgical stimulus. The novelty and the main strength point of our study is that this is the first study, up to our knowledge, that investigated preemptive ultrasound-guided SHPB in perioperative analgesia in a randomized, controlled trial.

The limitations and weak points of our study include the limited number of patients and limited follow-up time (24 h). We recommend further studies to involve a larger sample of patients and follow them for longer times.

Conclusion

We found that the US-guided SHPB via anterior approach is an effective and relatively safe technique to control pain of pelvic cancer surgeries.

Abbreviations

SHPB	Superior hypogastric plexus block
US	Ultrasound
VAS	Visual analogue scale
ASA	American Society of Anesthesia
PONV	Postoperative nausea and vomiting

Acknowledgements

We would like to thank all workers in the operating theatre in National Cancer Institute, Cairo, for their help in doing the study.

Authors' contributions

All authors contribute equally to all steps of this study.

Funding

This study was completely done by own funding by authors themselves with no external funding.

Availability of data and materials

All approvals, consents, and data of the patients and results are available upon request.

Declarations

Ethics approval and consent to participate

This study was conducted in National Cancer Institute, Cairo after obtaining institutional ethical committee board approval (IRB no: IRB0004025 on 22 June 2020) and clinical trial registration (NCT04732234). A written informed consent was obtained from each participant before the surgery.

Consent for publication

Written informed consent was taken from each patient before participating in this study.

Competing interests

The author declare that they do not have competing interests.

Received: 30 January 2023 Accepted: 9 September 2023

Published online: 21 September 2023

References

- Apfelbaum JL, Chen C, Mehta SS, Gan TJ (2003) Postoperative pain experience: results from a national survey suggest postoperative pain continues to be undermanaged. *Anesth Analg* 97(2):534–540
- Aytuluk HG, Kale A, Basol G (2019) Laparoscopic superior hypogastric blocks for postoperative pain management in hysterectomies: a new technique for superior hypogastric blocks. *J Minim Invasive Gynecol* 26:740–747
- Benhamou D, Berti M, Brodner G, Andres JD, Draisci G, MorenoAzcoita M et al (2008) Postoperative Analgesic Therapy Observational Survey (PATHOS): a practice pattern study in 7 central/southern European countries. *Pain* 136(1–2):134–141
- Binkert CA, Hirzel FC, Gutzeit A, Zollikofer CL, Hess T (2015) Superior hypogastric nerve block to reduce pain after uterine artery embolization: advanced technique and comparison to epidural anesthesia. *Cardiovasc Intervent Radiol* 38(5):1157–1161
- Cariati M, Martinin G, Pretolesi F, Roy MT (2002) CT-guided superior hypogastric plexus block. *J Comput Assist Tomogr* 26:428–431
- Carney J, McDonnell JG, Ochana A, Bhinder R, Laffey JG (2008) The transversus abdominis plane block provides effective postoperative analgesia in patients undergoing a total abdominal hysterectomy. *Anesth Analg* 107:2056–2060
- Dahl JB, Kehlet H (2011) Preventive analgesia. *Curr Opin Anaesthesiol* 24(3):331–338
- De Silva P, Daniels S, Bukhari ME, Choi S et al (2022) Superior hypogastric plexus nerve block in minimally invasive gynecology: a randomized controlled trial. *J Minim Invasive Gynecol* 29(1):94–102
- Gofeld M, Shankar H, Benzon HT (2018) Fluoroscopy and ultrasound guided sympathetic blocks. *Essentials Pain Med Elsevier*, p 804
- Kissin I (2000) Preemptive analgesia. *Anesthesiology* 93(4):1138–1143
- Le JM (1899) traitement de la neuralgie pelviene par la paralysie du sympathique sacre. *Lyon Med* 90:102–108
- Mishra S, Bhatnagar S, Rana SPS, Khurana D, MD, and Thulkar S (2013) Efficacy of the anterior ultrasound-guided superior hypogastric plexus neurolysis

- in pelvic cancer pain in advanced gynecological cancer patients. *Pain Med*;14:837–42
- Mishra S, Bhatnagar S, Gupta D, Thulkar S (2008) Anterior ultrasound-guided superior hypogastric plexus neurolysis in pelvic cancer pain. *Anaesth Intensive Care* 36(5):732–735
- Mishra S, Bhatnagar S, Rana SPS, Khurana D, Thulkar S (2013) Efficacy of the anterior ultrasound guided superior hypogastric plexus neurolysis in pelvic cancer pain in advanced gynecological cancer patients. *Pain Med* 14:837–842
- Peker H, Atasayan K, Peker BH, Kilicci C (2021) Intraoperative superior hypogastric plexus block for pain relief after a cesarean section: a case-control study. *Croat Med J* 62(5):472–479
- Plancarte R, Amescua C, Patt RB, Aldrete JA (1990) Superior hypogastric plexus block for cancer pelvic pain. *Anesthesiology* 7:236–239
- Plancarte R, de Leon-Casasola OA, El-Helaly M, Allende S, Lema MJ (1997) Neurolytic superior hypogastric plexus block for chronic pelvic pain associated with cancer. *Reg Anesth* 22:562–568
- Prithvi Raj P, Erdine S (2012) Pain-relieving procedures: the illustrated guide. Chapter 17: Interventional Pain Procedures in the Pelvic and Sacral Regions, 1st edn. John Wiley and sons Ltd, pp 365–371
- Rapp H, Ledin Eriksson S, Smith P (2017) Superior hypogastric plexus block as a new method of pain relief after abdominal hysterectomy: double-blind, randomized clinical trial of efficacy. *BJOG* 124(2):270–276
- Rocha A, Plancarte R, Natarén RGR, Carrera IHS, Pacheco VADR, Hernandez-Porras C (2020) Effectiveness of superior hypogastric plexus neurolysis for pelvic cancer pain. *Pain Physician* 23(2):203–208
- Sindt JE, Brogan SE (2016) Interventional treatments of cancer pain [review]. *Anesthesiol Clin* 34:317–339
- Waldman SD, Wilson WL, Kreps RD (1991) Superior hypogastric plexus block using a single needle and computed tomography guidance: Description of modified technique. *Reg Anesth* 16:286–287

Publisher's Note

Springer Nature remains neutral with regard to jurisdictional claims in published maps and institutional affiliations.

Submit your manuscript to a SpringerOpen[®] journal and benefit from:

- Convenient online submission
- Rigorous peer review
- Open access: articles freely available online
- High visibility within the field
- Retaining the copyright to your article

Submit your next manuscript at ► [springeropen.com](https://www.springeropen.com)
