

CASE REPORT

Open Access



Unilateral neurostimulation-assisted cervical epidural anesthesia for upper limb surgeries—a case series

Sandeep Diwan¹, Abhijit Nair^{2*} , Himaunshu Dongre¹ and Parag Sancheti³

Abstract

Background The role of neurostimulation-aided cervical epidural anesthesia (CEA) in shoulder surgery has been described in the literature. The use of nerve stimulators and the infusion of local anesthetic (LA) in the cervical epidural space has also been mentioned. Epidural needle rotation prior to insertion of the catheter is not described, and it is not clear if general anesthesia was administered in these cases.

Case presentation In this case series, we performed CEA at the level of C7-T1 in 12 patients undergoing various surgeries on the proximal open shoulder and mid humerus after informed consent. Ipsilateral motor responses elicited by continuous electrical stimulation were used to identify lateralization of the epidural catheter tip. The placement of catheters was confirmed under an intraoperative image intensifier. Using the median approach at the level of C7-T1, an ipsilateral twitch was noted in all patients. Neurostimulation persisted with an advancement of stimulating catheter 3–4 cm in the cervical epidural space in all patients. A cervical radiograph confirmed the placement of an ipsilateral catheter and contrast injection there upon revealing the spread of the LA agent. All patients had successful awake shoulder and mid-humerus surgeries under sole cervical epidural anesthesia as evidenced by the absence of pain response at the surgical incision.

Conclusions Ipsilateral CEA can be offered for unilateral upper limb surgeries. Low volumes of LA can be injected after precise placement of the tip of the catheter corresponding to the level of surgical incision.

Keywords Epidural anesthesia, Neurostimulation, Epidural, Local anesthesia, Surgery

Background

A continuous cervical epidural anesthesia (CEA) has been described in case reports to provide excellent postoperative analgesia for patients undergoing upper extremity surgery (Tsui et al. 2004a; Buchheit and Crews 2000; Prusinkiewicz et al. 2005). However, it is not commonly implemented as a sole anesthetic technique for

upper limb surgery. Though a caudal to thoracic catheter placement in pediatric patients is reported, a neurostimulation-guided cervical epidural placement of catheter from the upper thoracic route for shoulder surgeries in adults is also mentioned in the literature (Tsui et al. 2001).

In our case series, there was excellent unilateral anesthesia and analgesia which could be achieved with ipsilateral placement of the tip of the stimulating epidural catheter after rotating the epidural needle hub in the cervical epidural space.

*Correspondence:

Abhijit Nair
abhijitnair@rediffmail.com

¹ Department of Anesthesiology, Sancheti Hospital, Pune 411005, India

² Department of Anesthesiology, Ibra Hospital, Ministry of Health-Oman, P.O. Box 275, Ibra 414, Sultanate of Oman

³ Department of Orthopedics, Sancheti Hospital, Pune 411005, India



© The Author(s) 2023. **Open Access** This article is licensed under a Creative Commons Attribution 4.0 International License, which permits use, sharing, adaptation, distribution and reproduction in any medium or format, as long as you give appropriate credit to the original author(s) and the source, provide a link to the Creative Commons licence, and indicate if changes were made. The images or other third party material in this article are included in the article's Creative Commons licence, unless indicated otherwise in a credit line to the material. If material is not included in the article's Creative Commons licence and your intended use is not permitted by statutory regulation or exceeds the permitted use, you will need to obtain permission directly from the copyright holder. To view a copy of this licence, visit <http://creativecommons.org/licenses/by/4.0/>.

Case presentation

Informed consent was obtained from all patients and were counseled for the use of stimulating catheters and radio-contrast media for the spread of local anesthetic (LA). In 12 patients, a CEA was administered for the isolated proximal humerus, shoulder girdle stabilization, and shoulder disarticulation. Continuous CEA was performed in a sitting position on the operating table after securing an intravenous (IV) line and a continuous monitoring of heart rate with two lead ECGs and oxygen saturation. Precautions were taken in the event of a vasovagal shock (atropine, intubation cart).

After sterile preparation, with the patients awake and sitting, a 17-G Tuohy-stimulating needle (Arrow[®], Inc.) was inserted at the level of C7-T1 with a midline approach after skin infiltration with 4 ml of 1% lidocaine at the point of needle insertion. The cervical epidural space was identified with a loss of resistance technique, following which the catheter (Arrow[®], Inc.) was inserted. The epidural needle hub was rotated 90° on the side to be operated before catheter insertion. A nerve stimulator (B-Braun, USA) was connected to the stimulating epidural catheter with a stylet which was primed with 0.9% saline prior to threading. Electrical leads were positioned on the abdomen, and an electrical current (1–3 mA) was applied during advancement. Contractions of triceps, biceps, and deltoid muscles were observed and noted as the catheter was threaded. The side of the evoked motor response (EMR) and current was recorded for each patient if the twitch was unilateral. The end-point was the EMR of either the biceps or the deltoid muscles (C5–7). The catheter was secured with a sterile dressing (Tegaderm; 3 M Medical, USA). Patients were made to lie supine, and the tip of the radio-opaque catheter was located on the image intensifier in the antero-posterior and lateral views. With an ongoing continuous neurostimulation, the unilateral EMR was re-confirmed and an initial dose of 1 ml of iohexol (300 mg iodine/ml) diluted in 5 ml 0.5% bupivacaine was injected. The position of the catheter was confirmed on fluoroscopy after the initial dose. Analgesia was confirmed with a light pinprick after 20 min using a 26-G hypodermic needle. Top-ups of 0.5% bupivacaine were injected in aliquots of 1 ml when the surgeon complained of inadequate relaxation, patient bleated pain on the surgical incision and at the completion of the surgical procedure when pain first appeared. The total dose of LA injected (bolus and top-ups) was noted in all patients. All patients received IV midazolam 1–2 mg prior to surgical incision. The assessment was made during the surgical incision for pain, discomfort, and change in the heart rate. Three patients for shoulder disarticulation were sedated with a propofol infusion at 100 µg/kg/min, after surgical incision confirmed block

efficacy. Intraoperatively, patients were monitored with non-invasive blood pressure, electrocardiogram, and oxygen saturation. Intraoperative bradycardia or hypotension if any was recorded. An infusion of 0.1% ropivacaine at 5 ml/h was initiated immediately after the surgical procedure. Pain scores (visual analog scale) were monitored for the next 48 h at various time points (0, 6, 12, 24, and 48 h). Patients were assessed over 24 h for pain [visual analog scale pain scores 0–10 (VAS)] and side effects. IV diclofenac 75 mg was injected 12th hourly as a part of multimodal analgesia and intravenous tramadol 50 mg in 100 ml normal saline was prescribed as a rescue analgesic for a VAS more than 4. The amount of tramadol required was calculated in the first 24 h.

Block efficacy was considered adequate if there was no pain on incision, no supplementation of intravenous analgesics in the intraoperative period, and a VAS of not more than 4 in the postoperative period for the first 48 h. At the end of the 48th hour and completion of infusion, epidural catheters were removed. Prior to discharge patients were assessed for local neck pain and neurological complications, if any.

CEA was attempted in 12 patients, and surgeries were successfully conducted in 11 patients (4 males, 7 females). One patient with a dural puncture received general anesthesia. The mean age was 46.45 years, and the mean current at which the desired EMRs were achieved was 2.4 mA. With the needle hub rotation to the right, EMRs were successfully obtained in the right C5–6 myotomes in 7 patients and to the left in 4 patients. Images obtained with fluoroscope depicted the catheter tip (Fig. 1A) at vertebral levels of C5–6 in 8, at C6 in 2, and at C6–7 in 2 patients. The mean LA volume used initially and as a top-up dose was 8.08 and 4.72 ml, respectively. Contrast spread (Figs. 1B, 2A, B, 3A, B) was visualized from the lower end of C2 to the upper end of T3 with 5 to 10 ml of radiocontrast diluted in LA. The mean surgical duration was 78.66 min. The mean VAS score was 1.85 at the end of the 48th hour. Six patients required rescue analgesics (IV tramadol, mean of 75 mg). In patients who received propofol infusion for shoulder disarticulation, all awoke with VAS of 0, 1, and 2 in the postoperative recovery room. Intraoperative bradycardia in one patient and hypotension in three patients were noted after top-ups with LA. Hand grip was weak in 6 patients who received top-ups of LA and 4 among them had contralateral weakness in the immediate postoperative period. Catheters removed at the 48th hour were uneventful, and no local pain or neurological adverse effects were reported. The patient who suffered from a dural puncture did not complain of headaches or visual disturbances. Table 1 depicts the current used in milliamperes, the muscle in which evoked motor response was observed, the catheter

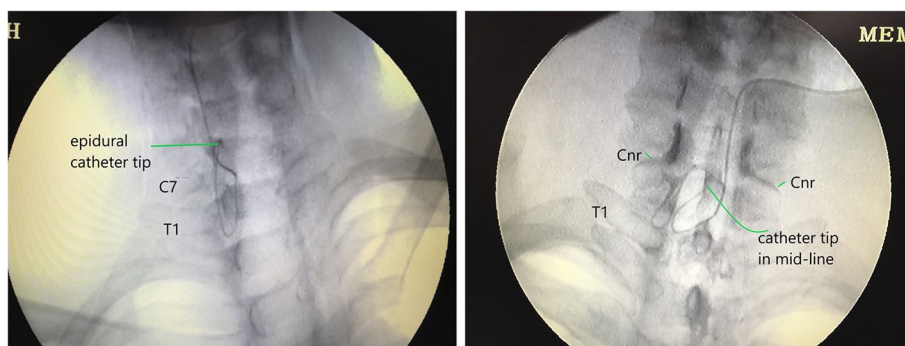


Fig. 1 **A** Catheter tip located in the lateral epidural space at the level of C6 vertebral level. **B** Catheter tip is lateral to the mid-line at the C6 vertebral level. Contrast injections delineate the cervical nerve roots (Cnr). T1, first costotransverse junction

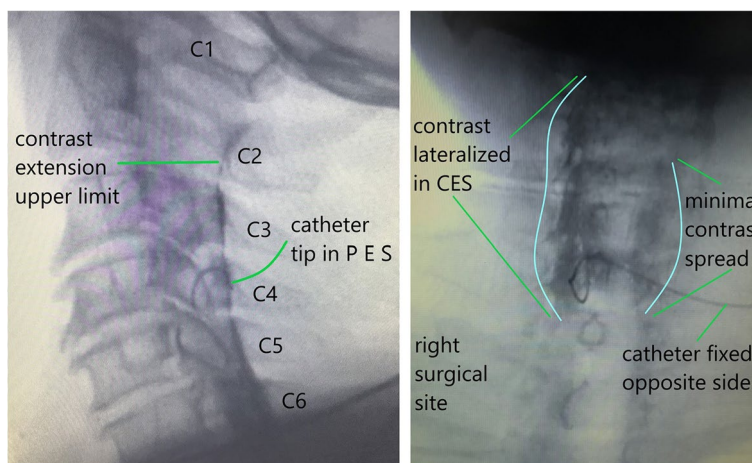


Fig. 2 **A** Catheter tip in the posterior epidural space (PES). The upper limit of contrast is at the C2 level. **B** Catheter tip is lateralized in the cervical epidural space with maximum contrast spread on the surgical side and minimal spread on the non-operative side

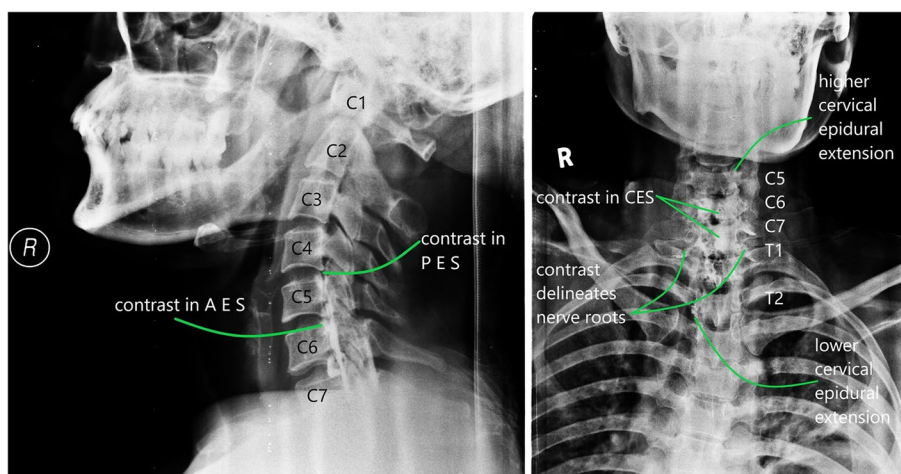


Fig. 3 **A** Lateral view: contrast spread in the posterior epidural space (PES) and anterior epidural space (AES) till the C5 upper vertebral level. **B** Anterior–posterior view: contrast injection depicting the spread from C5 till T2 and delineates the cervical nerve roots

Table 1 Showing current used, side of evoked motor response, catheter tip location, extent of contrast spread and local anesthetic used

Patient no	Current (mA)	Evoked motor response	Catheter tip location	Contrast spread	Local anesthetic in ml (0.5% bupivacaine)	
					Initial	Top-up
1	1.8	Right deltoid	C5-6	Upper-C5, lower-C7	5	0
2	2.7	Left deltoid	C5-6	Upper-C5, lower-T1	5	2
3	3.2	Right deltoid	C5-6	Upper-C4, lower-T1	7	6
4	2.4	Left biceps	C5-6	Upper- C3, lower-T3	10	8
5	2.1	Right deltoid	C5-6	Upper-C2, lower-T2	10	6
6	1.8	Right deltoid	C5-6	Upper-C4, lower-C7	6.5	0
7	2.4	Right biceps	C6-7	Upper-C3, lower-T3	10	4
8	2.9	Left deltoid	C6	Upper- C4, lower-T2	6.5	2
9	3.5	Right deltoid	C5-6	Upper-C3, lower-T2	7	6
10	2.4	Left biceps	C6-7	Upper-C3, lower-T3	10	8
11	1.9	Right deltoid	C5-6	Upper-C3, lower-T3	10	6

tip location, the contrast spread visualized, and the local anesthetic volume used.

Discussion

Neurostimulation of cervical epidural space has been reported earlier (Tsui et al. 2004a; Borghi et al. 2004). The catheters were introduced through a paramedian approach at the mid-upper thoracic space irrespective of the surgical site. The hypothesis of a right paramedian approach to position the catheter tip in the left cervical epidural space proved incorrect, as only 20% of catheters were threaded to the opposite side. The study did not mention the initial volume and the top-up of LA injected for a successful block. Catheters were lateralized successfully with rotation of the needle hub, and the level of the tip was confirmed with radiographic (image-intensifier) analysis in all patients. The beneficial effects of needle hub rotation are described in literature (Tsui et al. 2004b). All except 3 of our patients (shoulder disarticulation) were awake throughout the surgical procedure. Since shoulder disarticulation is an extremely unpleasant surgery, it was decided to sedate patients with continuous infusion of propofol after confirming block efficacy.

Lateralization of the catheter tip in the cervical epidural space is reported in a case report (Prusinkiewicz et al. 2005). As against bilateral block in all patients, we demonstrate unilateral block with volumes as low as 5–7 ml ($n=6$) with an initial bolus dose. Ipsilateral weakness of hand grip was noticed in 6 patients with an initial volume of 10 ml. None of the patients demonstrated bilateral blocks with top-ups of 2 ml injected 45 min apart. A continuous infusion of 0.1% ropivacaine at 5 ml/h with intravenous paracetamol 1 g injected 8 hourly did not warrant a rescue analgesic

in this study. The respiratory effects were unnoticed and cardiac events occurred in 6 patients. Though a study mentions that CEA decreases pulmonary functions (tidal volume, forced vital capacity, forced expiratory volume in the 1st second, and vital capacity), they become clinically significant only in patients with pre-existing respiratory pathology (Shanthanna et al. 2016). The experimental human cervical epidural study has proved that LA injection in the cervical epidural space depresses the sympathetic nervous system and baroreflex control of heart rate, resulting in bradycardia and hypotension (Tanaka et al. 2004).

Continuous CEA with a stimulating catheter does have limitations. It is not cost-effective. We suggest that this block should be performed by anesthesiologists who understand the intricacies of stimulating catheters and perceive a thorough knowledge of cervical epidural space. The patient population has to be selected (stoppage of anticoagulants/antiplatelets as per recommendations, severe pulmonary disorder, anatomic abnormality in the cervical area, obese patients with a pad of fat at the site of needle insertion are contraindications). This block could be offered in patients in whom interscalene block is an absolute or relative contraindication, i.e., who could develop respiratory compromise after the block (Hortense et al. 2010).

Patients who have respiratory issues (chronic obstructive pulmonary disease, bronchial asthma), requiring shoulder surgeries, are an anesthetic challenge. General anesthesia could be risky and techniques like interscalene block, and high thoracic epidural anesthesia can compromise existing respiratory conditions. We think our technique could be feasible and safer for such patients.

Conclusions

Through this limited case series, we suggest utilizing an ipsilateral CEA for unilateral upper limb surgeries. We recommend an appropriate lateral positioning of the catheter tip aided with neurostimulation below the level of C4 which will assist in reducing the volumes of LA for site-specific surgery.

Abbreviations

CEA	Cervical epidural anesthesia
LA	Local anesthetic
IV	Intravenous
EMR	Evoked motor response
VAS	Visual analog scale

Acknowledgements

Not applicable.

Authors' contributions

SD helped with the concepts, design, definitions of intellectual content, and manuscript preparation. AN helped in the literature review and manuscript editing. HD helped in the definition of the manuscript preparation and literature review. PS helped in the literature review. The authors have read and approved the manuscript.

Funding

Not applicable.

Availability of data and materials

Not applicable.

Declarations

Ethics approval and consent to participate

Ethical approval—Institutional Ethics Committee, Sancheti Hospital for Orthopedics & Rehabilitation; Date of approval: March 11, 2021. Written informed consent was obtained to participate from the participant.

Consent for publication

Consent to publication has been taken. Written informed consent was obtained from the participant.

Competing interests

The authors declare that they have no competing interests.

Received: 18 March 2023 Accepted: 16 August 2023

Published online: 28 August 2023

References

- Borghì B, Agnoletti V, Ricci A, van Oven H, Montone N, Casati A (2004) A prospective, randomized evaluation of the effects of epidural needle rotation on the distribution of epidural block. *Anesth Analg* 98:1473–1478
- Buchheit T, Crews JC (2000) Lateral cervical epidural catheter placement for continuous unilateral upper extremity analgesia and sympathetic block. *Reg Anesth Pain Med* 25:313–317
- Hortense A, Perez MV, Amaral JL, Oshiro AC, Rossetti HB (2010) Interscalene brachial plexus block. Effects on pulmonary function. *Rev Bras Anesthesiol* 60(130–7):74–8
- Prusinkiewicz C, Lang S, Tsui BC (2005) Lateral cervical epidural catheter placement using nerve stimulation for continuous unilateral upper extremity surgery analgesia following a failed continuous peripheral nerve block. *Acta Anaesthesiol Scand* 49:579–582

Shanthanna H, Mendis N, Goel A (2016) Cervical epidural analgesia in current anesthesia practice: systematic review of its clinical utility and rationale, and technical considerations. *Br J Anaesth* 116:192–207

Tanaka M, Goyagi T, Kimura T, Nishikawa T (2004) The effects of cervical and lumbar epidural anesthesia on heart rate variability and spontaneous sequence baroreflex sensitivity. *Anesth Analg* 99:924–929

Tsui BC, Seal R, Koller J, Entwistle L, Haugen R, Kearney R et al (2001) Thoracic epidural analgesia via the caudal approach in pediatric patients undergoing fundoplication using nerve stimulation guidance. *Anesth Analg* 93:1152–1155

Tsui BC, Bateman K, Bouliane M, Finucane B (2004a) Cervical epidural analgesia via a thoracic approach using nerve stimulation guidance in an adult patient undergoing elbow surgery. *Reg Anesth Pain Med* 29:355–360

Publisher's Note

Springer Nature remains neutral with regard to jurisdictional claims in published maps and institutional affiliations.

Submit your manuscript to a SpringerOpen® journal and benefit from:

- Convenient online submission
- Rigorous peer review
- Open access: articles freely available online
- High visibility within the field
- Retaining the copyright to your article

Submit your next manuscript at ► [springeropen.com](https://www.springeropen.com)