

CASE REPORT

Open Access



# Peripartum neurological complications and labor epidural: an anesthesiologist predicament

Mita Eunice Sarkar<sup>1\*</sup> , Alfred Inbaraj<sup>2</sup> and Pooja Rao<sup>3</sup>

## Abstract

**Background:** Dismissing the process of labor, postpartum neurological complications tend to implicate anesthetic interventions as the cause, a predicament to the anesthesiologist mandating utmost periprocedural vigilance.

**Case presentation:** Two obstetric patients with no comorbidities received uneventful labor epidurals. They presented with rare peripartum neurological complications.

**Conclusions:** Unrecognized dural puncture is often a retrospective diagnosis made with the onset of symptoms in a presumed uneventful epidural. Negative aspiration of cerebrospinal fluid (CSF) during epidural insertion does not completely rule out the dural puncture. The dural puncture can be obscured by initial dural tenting and tear without loss of CSF, followed by a breach in the weakened arachnoid during maternal efforts (Reynolds and Speedy, *Anaesthesia* 45:120-3, 1990). Obstruction of the TUOHY I umen with clot or ligamentum flavum, preventing CSF flow into the needle and subarachnoid migration of a subdurally placed catheter, is another cause.

Delay in management of neurological complications resulting from unrecognized dural punctures can occur.

**Keywords:** Cerebral venous thrombosis (CVT), Post-dural puncture headache (PDPH), Subdural hematoma (SDH), Arnold Chiari malformation (ACM), Unintentional dural puncture (UDP)

## Background

With increasing awareness of labor epidural among Indian women, a surge in demand has been witnessed in the recent past. Although rare, anesthesiologists should be aware of the peri-procedural neurological complications that can occur. We present two such complications, in parturients who received labor epidural at a tertiary teaching hospital.

## Case presentation

### Case 1

A 34-year-old primigravida, in active labor, requested epidural analgesia. Physical examination and routine

investigations were unremarkable. Lumbar epidural was secured uneventfully. A 3ml of 2% Lignocaine with Adrenaline as a test dose was administered after negative aspiration, followed by an infusion of 0.15% Ropivacaine at 10ml/h. She was co-loaded with a 500-ml crystalloid. Post-procedure vitals and fetal heart rate were stable. Modified Bromage score was 3–4.

She delivered normally 8 h later, with a forcep application for baby extraction. The inability to move the left upper and lower limbs was noticed the next morning. Neurological examination revealed normal higher mental functions, no facial asymmetry, grade 5/5 power on the right side, and 0/5 power on the left side. No sensory loss, and reflexes were bilaterally normal. The cerebellar system was not tested.

\*Correspondence: mitasarkar7@yahoo.com

<sup>1</sup> Department of Anaesthesiology, Bangalore Baptist Hospital, Hebbal, Bellary Road, Bangalore 560024, India

Full list of author information is available at the end of the article

### **Right cortical venous thrombosis (CVT) in the posterior high frontal region**

Magnetic resonance imaging (MRI) spine and echocardiography were normal. A thrombotic workup was done prior to initiation of anticoagulation, antithrombin III levels were low (68 %) due to the ongoing thrombosis. She received i.v Mannitol, anticoagulation, and physiotherapy. She was discharged on Warfarin to maintain INR2-3 and advised physiotherapy. A thrombotic workup repeated 3 months after stopping anticoagulation for 2 weeks was normal. The patient was reviewed 6 months later with no residual deficits (Fig. 1).

### **Case 2**

A 26-year-old primigravida delivered normally after receiving a single attempt of uneventful labor epidural. Post-discharge, day 3, she developed a debilitating occipital headache that worsened on sitting. With no history of chronic headache, trauma, or neurological deficits on examination, a diagnosis of post-dural puncture headache (PDPH) was made and managed accordingly. Worsening of headache despite medication prompted imaging. MRI brain: bilateral subdural collections R>L. The MRI spine was done to visualize an unintentional dural puncture (UDP) causing CSF loss. It surprisingly revealed caudal descent of cerebellar tonsils (7mm) through the foramen magnum with associated syringomyelia of the cervical spinal cord, suggestive of Arnold Chiari Malformation I (ACM) and normal lumbar spine. She was managed conservatively with anti-edema measures and prone positioning, resulting in symptomatic improvement within 5 days (Fig. 2).

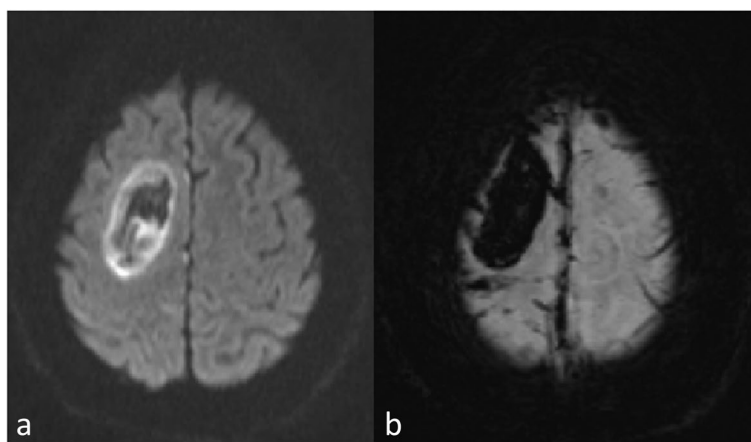
### **Discussion**

Pregnancy up to 8 weeks postpartum is a prothrombotic state, with the reported incidence of CVT being 0.018–0.20% (Kontogiorgi et al. 2012). After ruling out thrombophilias, risk factors of importance to the anesthesiologist are dural puncture and dehydration. Loss of CSF pressure and volume following a dural puncture results in compensatory venous volume expansion according to the Monroe Kellie doctrine with a 50% decrease of venous flow in the dural venous sinuses (Kate et al. 2014). Endothelial injury of cerebral blood vessels during maternal expulsive efforts or descent of the brain post-dural puncture completes Virchow's triad for thrombus formation (Wilder-Smith et al. 1997).

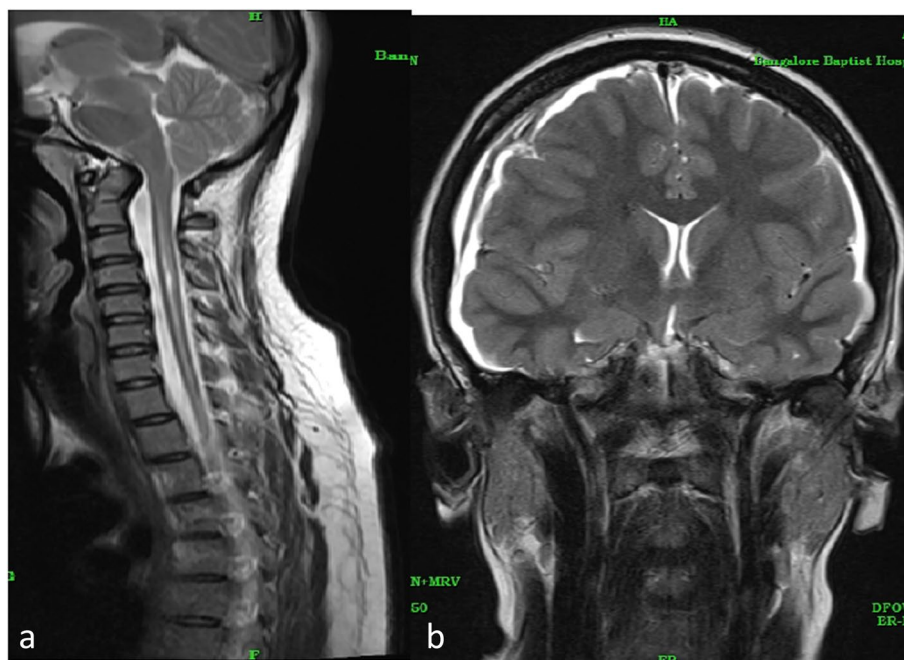
Adequate hydration is imperative despite an intact dura. Peripartum hypercoagulability accelerated by intrapartum volume depletion can trigger CVT.

Symptoms depend on the location of thrombus, collaterals, and cortical vein involvement. CVT commonly presents as headache, misdiagnosed as PDPH after the neuraxial blockade. Unlike PDPH, headache is subacute, non-positional, and changes in character, associated with neurological deficits (Kate et al. 2014). No peripartum headache should be taken lightly, as life-threatening causes like CVT, Posterior Reversible Encephalopathy Syndrome, undiagnosed ACM, and meningitis exist (Boushra and Rathbun 2019).

Forty-four percent manifest with focal neurological deficits like motor weakness (Piazza 2012). Our patient had CVT in the right pre-central gyrus causing left hemiplegia. She was able to maintain lithotomy and bear down, hence deficit may have occurred post-delivery.



**Fig. 1** **a** Diffusion weighted and **b** susceptibility weighted MRI sequences. Acute to subacute hemorrhagic infarction in the right posterior high frontal region probably due to cortical venous thrombosis. A few right posterior frontal cortical veins show blooming adjacent to the hemorrhagic infarction



**Fig. 2** a Low-lying tonsils with syringomyelia. b Bilateral subdural collections over cerebral hemispheres R>L, with hemorrhagic content, mild mass effect causing compression of ventricles, low-lying tonsils, and midline shift—3.8mm to left, suggestive of intracranial hypotension

Motor block, a side effect of epidural analgesia can be minimized using a lower concentration of local anesthetic or one having a high differential sensory: motor block ratio like Ropivacaine (Wang et al. 2010). 0.2% of Ropivacaine causes greater motor blockade as compared to 0.05–0.15% (Boushra and Rathbun 2019). We administered 0.15% of Ropivacaine. The addition of opioids decreases the concentration of local anesthetic used; however, this can cause pruritis, nausea, respiratory depression, and lower APGAR scores (Wang et al. 2010). We avoid opioids in labor epidural at our institution.

A subdural hematoma can mimic PDPH, occurring 1:250,000–1:500,000 after unintentional dural puncture (Palot et al. 1994). Higher incidence is noted with pre-existing aneurysms, arachnoid cysts, and vascular malformations (Peralta and Devroe 2017). Dural puncture causes CSF loss, traction, and damage to vascular structures (Peralta and Devroe 2017). Symptoms include vomiting, visual disturbances, impaired consciousness, and focal deficits (Peralta and Devroe 2017).

International Classification of Headache Disorders II criteria for PDPH include all of the following:

- 1) Headache worsening within 15 min of sitting/standing, improving within 15 min of lying supine
- 2) Accompanied by at least one: nausea, photophobia, hypacusia, and tinnitus
- 3) Within 5 days of dural puncture
- 4) Resolving spontaneously within 1 week or 48 h of effective treatment of CSF leak, usually epidural blood patch (Silberstein et al. 2005)

Any headache inconsistent with these criteria should be monitored for worsening despite medical management and imaging being mandated (Silberstein et al. 2005).

ACM 1, seen in adults, is a congenital anomaly with herniation of cerebellar tonsils >5mm into or below the level of the foramen magnum due to the underdeveloped occiput (Teo 2018). The presence of a syrinx implies initial or persistent communication between the syrinx and CSF in the central canal (Teo 2018). The clinical spectrum varies from asymptomatic to suboccipital radiating headache, and ocular and sensory-motor disturbances (Ghaly et al. 2012).

Physiological increase in cerebrospinal fluid (CSF) pressure occurs during pregnancy, with an acute increase during the second stage of labor (Ghaly et al. 2012). Understanding CSF outflow is crucial for aesthetic management.

Intermittent obstruction to CSF outflow from the fourth ventricle causes the development of pressure gradients, with higher intracranial CSF pressure as compared to spinal CSF pressure (Teo 2018). Central

neuraxial blockade (CNB) worsens the gradient, causing compression of cerebellar tonsils and a cervical cord or obstructive hydrocephalus that can manifest later (Teo 2018).

Minimizing CSF loss < 2ml during subarachnoid block and use of boluses < 5 ml via epidural have been advocated, as 10 ml boluses cause a transient increase in intracranial pressure (ICP) up to 21 mmHg for 4.5 min by compressing the dural sac, altering compliance of subarachnoid space and displacing CSF into the cranium (Ghaly et al. 2012). We used a loss of resistance to saline technique and a 3ml bolus of test dose.

Spinal deformities and autonomic neuropathy causing life-threatening perioperative hemodynamic instability are associated with ACM, mandating detailed pre-anesthetic neurological assessment (Teo 2018).

In a retrospective analysis with a high utilization rate of CNB in ACM parturients, no worsening of symptoms was recorded. The incidence of UDP was similar to parturients without ACM, but with an increased risk of PDPH in those with syringomyelia (Gruffi et al. 2019).

General anesthesia acutely increases intracranial pressure (ICP) during intubation and neck extension. Awake fibreoptic intubation has been used to avoid this hazard (Ghaly et al. 2012). An increased sensitivity to neuromuscular blockers occurs; therefore, avoiding its use or intraoperative neuromuscular monitoring is suggested (Ghaly et al. 2012). Mild hyperventilation and post-delivery osmодиuresis maintain ICP. Neurological assessment prior to extubation followed by smooth emergence from general anesthesia is essential (Ghaly et al. 2012).

With no randomized control trials comparing GA versus CNB for ACM1 parturients, multidisciplinary management weighing risks against benefits, with an individualized approach is necessary. Ghaly et al. have comprehensively constructed a decision-making tree consisting of symptomatology and radiological findings to guide anesthetic management (Ghaly et al. 2012).

## Conclusions

Case 1 did not have a headache throughout her hospital stay, MRI spine post-procedure showed no loss of CSF, and CVT likely is being precipitated by dehydration in a hypercoagulable state. An incidental ACM 1 in Case 2 could have manifested due to the epidural bolus altering CSF flow. However, unrecognized dural puncture cannot be ruled out in both cases, making it imperative for the anesthetist to understand rare peripartum neurological implications of labour epidural. Follow-up of patients who had an UDP and those who complain of post-procedural headache by the anesthesiologist may prove beneficial for early detection and appropriate management of

complications (Cohen et al. 2004; Reynolds and Speedy 1990).

## Abbreviations

MRI: Magnetic resonance imaging; INR: International normalized ratio; UDP: Unintentional dural puncture; PDPH: Post-dural puncture headache; ACM: Arnold Chiari malformation; CVT: Cerebral venous thrombosis; SDH: Subdural hematoma; CSF: Cerebrospinal fluid; CNB: Central neuraxial blockade; ICP: Intracranial pressure.

## Acknowledgements

Nil

## Authors' contributions

MES collected the patient data and wrote, designed, and finalized the manuscript. AI and PR helped in the editing, reviewing, and finalizing of the manuscript. The authors read and approved the final manuscript.

## Funding

Nil

## Availability of data and materials

Not applicable as the manuscript contains no data.

## Declarations

### Ethics approval and consent to participate

The case report has been approved for publication by the Institutional Review Board of Bangalore Baptist Hospital. Written informed consent was obtained from the patients.

### Consent for publication

Written informed consent was obtained from the patients for the purpose of publication.

### Competing interests

The authors declare that they have no competing interests.

### Author details

<sup>1</sup>Department of Anaesthesiology, Bangalore Baptist Hospital, Hebbal, Bellary Road, Bangalore 560024, India. <sup>2</sup>Department of Radiology, Bangalore Baptist Hospital, Hebbal, India. <sup>3</sup>Department of Anesthesiology, Bangalore Baptist Hospital, Hebbal, Bangalore, India.

Received: 21 February 2022 Accepted: 30 September 2022

Published online: 08 November 2022

## References

- Boushra M, Rathbun KM (2019) Postpartum headache. Stat Pearls Publishing, Treasure Island
- Cohen S, Casciano M, Bhausar V (2004) Unrecognised dural punctures—revisited. *Int J Obstetric Anesthesia* 13:57–58
- Ghaly RF, Candido KD, Sauer R, Knezevic NN (2012) Anesthetic management during Cesarean section in a woman with residual Arnold-Chiari malformation Type I, cervical kyphosis, and syringomyelia. *Surg Neurol Int* 3:26
- Gruffi TR, Peralta FM, Thakkar MS, Arif A et al (2019) Anesthetic management of parturients with Arnold Chiari malformation-I: a multicentric retrospective study. *Int J OA* 37:52–56
- Kate MP, Thomas B, Sylaja PN (2014) Cerebral venous thrombosis in post-lumbar puncture intracranial hypotension: case report and review of literature. *F1000Research*. 3:41. <https://doi.org/10.12688/f1000research.3-41.v1>
- Kontogiorgi M, Kalodimou V, Kollias S, Exarchos D et al (2012) Postpartum fatal cerebral vein thrombosis: a case report and review. *Open J Clin Diagnostics*. 2:1–3

- Palot M, Visseaux H, Botmans C, Pire JC (1994) Epidemiology of complications of obstetrical epidural analgesia [in French]. *Cah Anesthesiol.* 42:229–233 [PubMed: 8087639]
- Peralta F, Devroë S (2017) Any news on the postdural puncture headache front? *Best Pract Res Clin Anaesthesiol* 31:35–47
- Piazza G (2012) Cerebral venous thrombosis. *Circulation* 125(13):1704–1709
- Reynolds F, Speedy HM (1990) The subdural space: the third place to go astray. *Anaesthesia* 45:120–123
- Silberstein SD, Olesen J, Bousser MG, Diener HC, Dodick D, First M et al (2005) The International Classification of Headache Disorders, 2nd Edition (ICHD-II)—revision of criteria for 8.2 Medication-overuse headache. *Cephalalgia* 25:460–465 [PubMed: 15910572]
- Teo MM (2018) Spinal neuraxial anaesthesia for cesarean section in a parturient with type I Arnold Chiari Malformation and syringomyelia. *Sage Open Med Case Rep* 6:1–3
- Wang LZ, Chang XY, Liu X, Hu XX, Tang BL (2010) Comparison of bupivacaine, ropivacaine and levobupivacaine with sufentanil for patient-controlled epidural analgesia during labor: a randomized clinical trial. *Chin Med J (Engl)* 123:178–183
- Wilder-Smith E, Kothbauer-Margreiter I, Lämmle B, Sturzenegger M, Ozdoba C, Hauser SP (1997) Dural puncture and activated protein C resistance: risk factors for cerebral venous sinus thrombosis. *J Neurol Neurosurg Psychiatry* 63(3):351–356

### Publisher's Note

Springer Nature remains neutral with regard to jurisdictional claims in published maps and institutional affiliations.

Submit your manuscript to a SpringerOpen<sup>®</sup> journal and benefit from:

- ▶ Convenient online submission
- ▶ Rigorous peer review
- ▶ Open access: articles freely available online
- ▶ High visibility within the field
- ▶ Retaining the copyright to your article

---

Submit your next manuscript at ▶ [springeropen.com](https://www.springeropen.com)

---