

CASE REPORT

Open Access



Iatrogenic operative hysteroscopic intravascular absorption syndrome: a recurring possibility!

Reena Ravindra Kadni^{1*} , Mita Eunice Sarkar¹, Indira Menon² and Anne Marie Kongari³

Abstract

Background: Operative hysteroscopic intravascular absorption syndrome (OHIA) is the constellation of signs and symptoms due to fluid overload during hysteroscopic procedures. It can present with hyponatremia, deranged coagulation, pulmonary, and cerebral edema which are life-threatening issues. To our knowledge, this is the first reported case of recurrent OHIA syndrome which was managed uneventfully.

Case presentation: A 26-year-old American Society of Anesthesiologist (ASA) patient presented with primary infertility and prolonged, heavy menstruation. The abdominal and transvaginal ultrasound (USG) revealed a large posterior intramural fibroid of size 6.1 cm × 4.2 cm with submucosal intracavitary extension. She was planned for two-step laparoscopic and hysteroscopic evaluation and resection of the myoma under general anesthesia. Severe OHIA syndrome occurred with 1.5% glycine in phase 1 resection and recurred with 0.9% sodium chloride in phase 2 resection of intrauterine myoma at two different surgical settings. The uniqueness of this case is recurrence of OHIA syndrome in the same patient despite the use of normal saline (NS) due to lack of precautionary measures for fluid management.

Conclusions: Normal saline as an irrigating medium may not eliminate the risk of OHIA. Lack of adequate fluid management strategies can be detrimental especially in cases of hysteroscopic myoma resections. Following a standard protocol for vigilant monitoring under general anesthesia is the key in successful management.

Keywords: Glycine, Hysteroscopy, Iatrogenic, Intravascular absorption syndrome, Normal saline, Recurrence

Background

The incidence of classical operative hysteroscopic intravascular absorption (OHIA)/gynecological TURP syndrome is less than 1% (Hahn, 2006). To our knowledge, the recurrence of OHIA in the same patient despite all precautionary measures is not reported yet.

Hysteroscopic procedures are routinely employed for endometrial ablation, septum resection, myomectomy, or polypectomy. The absorption of fluid depends on the

extent of transection of vascular beds, intrauterine distention pressures, duration of the procedure, and surgical experience. Fluid balance is a critical issue during these surgeries.

The institutional review board of our hospital has approved the case report and written informed consent is taken from the patient.

Case presentation

A 26-year-old American Society of Anesthesiologist (ASA) physical patient with 61 kg weight and 155 cm height presented with primary infertility and prolonged, heavy menstruation to our hospital. She had no concomitant comorbid issues. The abdominal and transvaginal ultrasound revealed a large posterior intramural

* Correspondence: docreena1@gmail.com

This case report was selected by AOA 2017 conference Bangalore for free paper presentation. Paper presentation was done by Dr. Reena Ravindra Kadni on 1st October 2017.

¹Department of Anaesthesia, Bangalore Baptist Hospital, Bellary Road, Hebbal, Bangalore 560024, India

Full list of author information is available at the end of the article

fibroid of size 6.1 cm × 4.2 cm with submucosal intracavitary extension. A two-step plan of laparoscopic and hysteroscopic evaluation and resection under general anesthesia (GA) was made. Baseline hemodynamic parameters were blood pressure of 130/80 mmHg, heart rate of 98/min, and saturation of 100%. With standard monitoring, anesthesia was administered with intravenous (IV) fentanyl 2 mcg.kg⁻¹, propofol 2 mg.kg⁻¹, and atracurium 0.5 mg.kg⁻¹ and airway secured with size 7 cuffed tracheal tube. Maintenance of GA was done with oxygen (50%): air: (50%), isoflurane to minimum alveolar concentration (MAC) one and analgesia with morphine 0.1 mg.kg⁻¹. The patient was put on mechanical ventilation (MV) in volume control mode and positioned in lithotomy.

Hysteroscopic resection was started with Karl Storz hysteroscope with 1.5% glycine with intrauterine pressure assuming to be limited to 60–80 mmHg by adjusting the height of the irrigation fluid to 40 in. Intravenous fluid was restricted to 250 ml.h⁻¹ of Ringer lactate solution. Duration of resection was 80 min, at the end of which we noticed a sudden onset of facial puffiness and abdominal tightness on uncovering the patient.

IV furosemide titrated to 50 mg and positive end expiratory pressure of 7 cmH₂O was applied as gurgling in the bag was noted with spontaneous breathing efforts and auscultation revealed bilateral coarse crepitations. Urine output (U/O) was 2.4 l. Due to delayed recovery and inadequate respiratory efforts; patient was shifted on MV to intensive care unit (ICU). An approximation of 1.5 l glycine deficit was evident following calculation of used and efflux of glycine from drapes, suction, and resectoscope. Laparoscopic evaluation was abandoned in view of the complication.

In the ICU, the patient had vaginal bleed and investigations revealed severe hyponatremia, hypomagnesemia, and deranged coagulation (Table 1). D-dimer levels were > 20,000 ng/dL which indicated an ongoing activation of the hemostatic system. Echocardiographic findings were normal. With FiO₂ of 50%, ABG: pH—7.38, pCO₂—30.5, pO₂—200, HCO₃—17.7, BE—6. Calculated A-a gradient was 500 mmHg indicating pulmonary involvement. A diagnosis of OHIA syndrome was confirmed. She was managed with fluid restriction, 3% sodium chloride correction 10 ml.h⁻¹, furosemide infusion 5 mg.h⁻¹ and fresh frozen plasma 15 ml.kg⁻¹ correction

Table 1 Blood investigations following OHIA at phases 1 and 2 surgical setting

Investigations	Normal range	1.5% Glycine						0.9% Normal saline		
		Preop	Immediate post-resection	12-h post-op	1st postop day	2nd postop day	3rd postop day	Preop	Immediate post-surgery	1st postop day
Hemoglobin	12–16 g/dL	13.7	12.3	10.2	9.7	7.8	8.5	12.1	8.5	11.2
Packed cell volume (%)			36.4		29	23.4	26.5			
Total count	4–10 × 10 ³ /mm ³		23.5			14.8	7.7	7.0	7.7	6.5
Platelets	150–400 × 10 ³ /mm ³	278	270			149	207	286	207	228
Creatinine	0.5–1.1 mg/dL	0.9	0.68		0.75	0.74		0.62		
Sodium	135–145 mmol/L	137	87	116	134	135	134	134	135	135
Potassium	3.5–5 mmol/L	3.6	4.3		3.1	3.6	3.7	3.7	3.7	3.4
Calcium	8.3–10.4 mg/dL	8.8	5.2	8.4	9.0	8.2		8.2	7.3	8.2
Magnesium	1.8–2.4 mg/dL		0.8		1.6			2.4	0.9	2.2
Chloride	96–106 mmol/L		85			106				
PT/control	12–14 s		76/13		19/13	18/13	15.7/13	12.5/12	15/13	13/11
INR	1–1.5		9		1.53	1.47	1.17	0.92	1.17	1.19
APTT/control	25–32 s		82/29		30/29	28/29	28.6/29	27/28	28/29	27/29
Albumin	3.5–5 g/dL		3.6						3.6	

and MV. Calcium and magnesium corrections were also done simultaneously. Total counts were 23,000/mm³ and she was treated with antibiotic to prevent sepsis. Blood transfusion was not done as her immediate hemoglobin level was 12.3 g/dL. Serial hemoglobin measurements were done to assess the blood loss postoperatively.

After 24 h, all investigations were normal, and patient was extubated uneventfully.

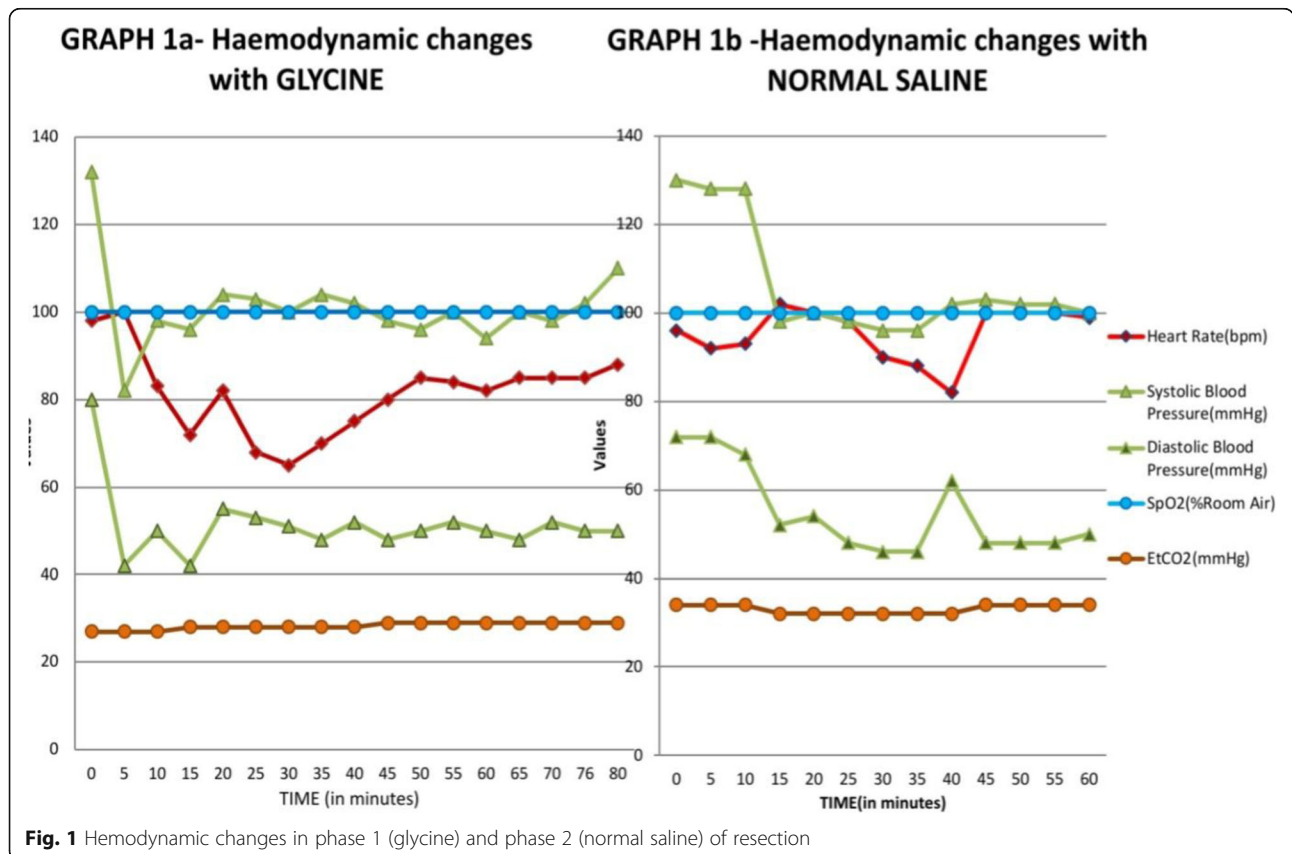
The patient was planned for phase 2 resection of the remnant submucosal intracavitary myoma of size 2.3 × 1.3 cm after three months. Apart from standard precautions, the duration of resection was limited and normal saline (NS) was used for irrigation with fluid absorption analysis every 10 min. GA with tracheal intubation was administered due to the similar planned surgical procedure. At 45 min, towards the end of procedure, facial swelling was observed, and auscultation revealed conducted sounds. IV titrated furosemide 70 mg was given. Extubation was done after a cuff leak test. Blood tests revealed serum sodium (S. Na):135 mmol/l, hypomagnesemia and normal coagulation profile (Table 1). A NS deficit of 1.5 l was observed. U/O was 1 l. A recurrence of OHIA was diagnosed. A drop in hemoglobin was observed at both times.

Intraoperatively, there was a drop in hemodynamic variables of more than 20% following induction of anesthesia in the first 10–15 min and thereafter it was stable during both phases of resections. EtCO₂ remained in the normal range as laparoscopy resection was not done at both surgical settings and patient’s ventilation was controlled well with MV once signs of OHIA were discovered (Fig. 1).

Discussion

Though minimally invasive, hysteroscopic surgeries can be associated with complications like uterine perforation, bleeding, infection fluid overload, and incomplete resections (Aas-Eng et al., 2017). Myomectomy by hysteroscopic procedure takes the longest time to heal, around 2–3 months because of the depth of myomectomy wounds although time taken for the endometrium to heal completely is not clearly recognized (Yang et al., 2013).

OHIA can present with signs like bradycardia, hypotension, oxygen desaturation, increased peak airway pressures and decreased end tidal carbon dioxide can manifest intraoperatively under GA (Sethi et al., 2012). ‘Parotid area sign’ has been described in literature to detect early onset of fluid overload with glycine use (Sinha et al., 2007). None of these signs were observed



intraoperatively in our patient. Neuraxial anesthesia may benefit early neurological detection of hyponatremia but not helpful if laparoscopic evaluation/surgery is planned by the surgeons.

Sethi et al. observed an abrupt onset OHIA syndrome with the use of glycine with

S. Na:100 mmol/L and INR:1.94 (Sethi et al., 2012). The laboratory and clinical picture of our patient was comparatively critical with S. Na: 80 mmol/L and INR:9. The extremely deranged INR status could have resulted from dilutional coagulopathy, consumption coagulopathy, loss of coagulation factors with blood loss, and enhanced fibrinolysis from glycine toxicity (Istre et al., 1995). The high d-dimer levels reflect fibrinolysis. Measurement of fibrinogen levels and point of care thromboelastography could have added further insights. However, these were not available then in our laboratory. The estimation of glycine absorption may not be accurate in our case as traditional rough methods ways of calculating fluid balance can be inappropriate. Frusemide and fluid restriction were the main stay of treatment for hypervolemic hyponatremia in our case and 3% NaCl was given at a slow rate.

Electrolyte were not disturbed with NS induced OHIA syndrome and similar observations were seen in our case (Santos & Coelho, 2019). Early finding of facial swelling helped the team to manage the patient immediately. Ji-Yong Kim reported a similar case due to massive 0.9% NaCl absorption and prolonged duration of surgery and concluded that hysteroscopic myomectomies are at higher risk (Kim et al., 2013). In our case, the OHIA developed within 45 min and with 1.5 l calculated deficit of NS, which could have been undercalculated due to concealed fluid absorption and high vascularity of the myoma with incomplete healing.

It is advised to halt the procedure and check electrolytes with a glycine deficit of 1000 ml. With NS, fluid deficit can be more liberal, up to 2500–3000 ml (Sameer Umranikar et al., 2016). A fluid deficit of 1000 ml corresponds to a drop in serum sodium levels by 10 mmol/L (Istre et al., 1994). This was the limitation in our case where electrolytes were not done with a 1000-ml glycine deficit. Lack of device to measure intrauterine pressure was another concern.

A protocol under GA with serial electrolyte measurements, echocardiographic or lung ultrasound monitoring of fluid status, ethanol breath test, and observing for the parotid area sign should be emphasised (Chauhan et al., 2018).

Fluid absorption can be decreased by keeping the intrauterine pressure or fluid pressures less than the mean arterial pressure, using appropriate distension media and delivery systems, and significantly keeping operative times to a minimum. The traditional

volumetric and gravimetric methods of fluid absorption analysis may not be accurate. Newer automated fluid management systems may prove better. This may take a long way to go in developing countries.

Hyponatremia, hypocalcemia, and hypomagnesemia were observed in both settings which could be attributed to dilutional effect, loss, and use of frusemide. There was a mild decrease in hemoglobin initially following the development of OHIA which could be due to use of loop diuretic and lack of redistribution. A drop in hemoglobin was observed gradually in the postoperative period which could have resulted from both concealed blood loss, deranged coagulation and hemolysis (Istre et al., 1995) due to glycine toxicity.

A differential diagnosis of sepsis with increased total counts, concealed blood loss with hemodilution and glycine toxicity reflecting as a progressive drop in hemoglobin and deranged coagulation can be suspected in our case.

In our case, there was occurrence of an extreme degree of OHIA with glycine and recurrence of milder form of it with NS. Limitation in duration of surgery and use of NS with bipolar cautery proved helpless to prevent OHIA. Unphysiological laboratory values with glycine could have resulted from misinterpretation in fluid calculation and glycine toxicity.

Use of glycine, prolonged duration of surgery, hysteroscopic myomectomy, incomplete healing of endometrial tissues from previous surgeries, lack of fluid management strategies, and intrauterine pressure monitoring, failure to practice prophylactic use of diuretics, faltering communication with surgeons to stop the surgery, loss of practice of performing a regular clinical examination of patient under general anesthesia, failure to use point of care intraoperative lung USG, and serial measurements of electrolytes add as contributing list of factors in our case.

Conclusions

Normal saline as an irrigating medium may not eliminate the risk of OHIA. Precautions and preventive measures with anticipation of complications should be specifically considered in high-risk procedures like hysteroscopic resection of myomas.

Iatrogenic OHIA can occur with lack of appropriate fluid management strategies with a possibility of concealed fluid absorption. Vigilance and early intervention rest with the anesthesiologist.

Abbreviations

OHIA: Operative hysteroscopic intravascular absorption syndrome; ASA: American Society of Anesthesiologists; GA: General anesthesia; IV: Intravenous; MAC: Minimum alveolar concentration; MV: Mechanical ventilation; ICU: Intensive care unit; U/O: Urine output; NS: Normal saline; USG: Ultrasound

Acknowledgements

Dr. Shreyas and Dr. Balachandra from departments of hematology and pathology respectively for their guidance in analysis of laboratory results. Dr. V Zachariah, MD Anesthesia, support as Head of the department. Dr. G Korula, MS, Head of the department RMU for their support. Dr. Sharmista Shukla and Dr. Kouser B, DNB postgraduates for their support in clinical management of the case. Dr. Archana Srinath, DNB postgraduate for her technical help.

Authors' contributions

RRK helped in collection, writing, designing, revision, and finalizing the manuscript. MES and IM were involved in reviewing, correcting, and finalizing the article. AMK helped in revising the article. The manuscript is read and approved by all authors. The requirements for authorship are fulfilled and we believe this represents honest work.

Funding

None.

Availability of data and materials

Not applicable

Declarations**Ethics approval and consent to participate**

Institutional review board of Bangalore Baptist Hospital has approved for the publication of this case report and informed written consent is taken from the patient.

Consent for publication

Written informed consent was taken from the study patient for the purpose of publication.

Competing interests

All authors declare that they have no competing interests.

Author details

¹Department of Anaesthesia, Bangalore Baptist Hospital, Bellary Road, Hebbal, Bangalore 560024, India. ²Critical Care Department, Bangalore Baptist Hospital, Bellary Road, Hebbal, Bangalore 560024, India. ³Department of Reproductive Medicine Unit, Bangalore Baptist Hospital, Bellary Road, Hebbal, Bangalore 560024, India.

Received: 17 February 2021 Accepted: 18 December 2021

Published online: 10 January 2022

References

- Mee Kristine Aas-Eng, Anton Langebrette, Gernot Hudelist. Complications in operative hysteroscopy - is prevention possible? *Acts Obstetrician et Gynecologica Scandinavia* 2017; 96. Issue 12.18
- Chauhan R, Ganesan V, Luthra A (2018) Operative hysteroscopy intravascular absorption syndrome: The gynaecological transurethral resection syndrome. *Obstet Anaesthesia. Crit Care* 8(2):112–114
- Hahn RG (2006) Fluid absorption in endoscopic surgery. *Br J Anaesth* 96:8–20
- Istre O, Bjoennes J, Naess R, Hornbaek K (1994) Forman A Postoperative cerebral oedema after transcervical endometrial resection and uterine irrigation with 1.5 % glycine. *Lancet* 344:1187–1189
- Istre O, Jellum E, Skajaa K, Forman A (1995) Changes in amino acids, ammonium, and coagulation factors after transcervical resection of the endometrium with a glycine solution used for uterine irrigation. *Am J Obstet Gynecol* 172(3):939–945
- Kim J-y, Chae M, Lee J (2013 Dec) Operative hysteroscopy intravascular absorption syndrome caused by massive absorption of 0.9% saline as the distention/irrigation medium. *Korean J Anesthesiol* 65(6 Suppl):S44–S46
- Sameer Umranikar, T. Justin Clark, Ertan Saridogan, et al and British Society for Gynaecological Endoscopy /European Society for Gynaecological Endoscopy Guideline Development Group for Management of Fluid Distension Media in Operative Hysteroscopy. *BSGE/ESGE guideline on management of fluid distension media in operative hysteroscopy. Gynecological surgeries.* 2016; 13(4): 289-303.

Ana Margarida Silva Santos, Daniela Coelho. Operative Hysteroscopy Intravascular Absorption Syndrome: The Gynaecology's TURP Syndrome-A Case Report *Anaesthesiology and Pain Medicine.* 2019; 9(3): e90285. doi: <https://doi.org/10.5812/aapm.90285>.

Sethi N, Chaturvedi R, Kumar K (2012) Operative hysteroscopy intravascular absorption: A bolt from the blue. *Indian. J Anaesthesia* 56(2):179–182

Sinha M, Hegde A, Sinha R, Goel S (2007) Parotid area sign: A clinical test for the diagnosis of fluid overload in hysteroscopic surgery. *J Minim Invasive Gynecol* 14:161–168

Yang J-H, Chen M-J, Chen C-D et al (2013 Jun) Optimal waiting period for subsequent fertility treatment after various hysteroscopic surgeries. *Fertility Sterility* 99(7):2092–2096

Publisher's Note

Springer Nature remains neutral with regard to jurisdictional claims in published maps and institutional affiliations.

Submit your manuscript to a SpringerOpen[®] journal and benefit from:

- Convenient online submission
- Rigorous peer review
- Open access: articles freely available online
- High visibility within the field
- Retaining the copyright to your article

Submit your next manuscript at ► [springeropen.com](https://www.springeropen.com)