

CASE REPORT

Open Access



Anesthetic management of complicated placenta percreta

Rajnish Kumar^{1*}, Nishant Sahay¹, Shagufta Naaz¹ and Rajesh Kumar²

Abstract

Background: Placenta percreta is a severe form of placenta accreta in which the placenta penetrates the entire uterine wall and attaches to another organ such as the bladder and bowel. It gives rise to a major obstetric hemorrhage, peripartum hysterectomy, and maternal and fetal morbidity and mortality.

Case presentation: I present a 34-year-old female of 24 week gestation a case of placenta percreta with a history of bleeding per vagina for the last 1 month for that she received 11 units of blood transfusion. Placenta percreta with fetal demise was diagnosed in magnetic resonance imaging on admission. Uterine artery embolization was done to reduce perioperative bleeding. Hysterectomy was done successfully with the multidisciplinary team approach under general anesthesia.

Conclusions: So, proper preoperative planning and good communication with the multidisciplinary approach will make a better outcome in these types of cases.

Keywords: Placenta percreta, Hemorrhage, Fetal demise

Background

Hemorrhage in obstetric patients is the most common cause of maternal morbidity and mortality (Say et al., 2014). In the placenta percreta, chorionic villi penetrate in the full myometrium and adjacent organs like the bladder. Bladder invasion by the placenta can lead to potentially life-threatening obstetric complications. I present a case report of placenta percreta with fetal demise which was successfully managed with planned hysterectomy under general anesthesia.

Case presentation

A 34-year-old female of 24-week gestation was transferred to this institution with a complaint of painless bleeding per vagina for the last 1 month. A large amount of clotted for 3 days, and she had complained of pain in the abdomen, high-colored urine, pruritus, and constipation for the last 20 days. She had a previous history of two lower segment cesarean sections (LSCSs). She

received 11 units of PRBC over the last 1 month along with antibiotic and hepatoprotective drugs. On examination, her pulse was 80 beats/min, blood pressure 110/60 mm Hg, and pallor and icterus were present. Her hemoglobin was 8.6 gm% and INR 1.7. She received 1 unit of packed red blood cell (PRBC) and 3 units of fresh frozen plasma (FFP). Magnetic resonance image (MRI) revealed fetal demise, high-grade complete placenta previa, placenta overlying internal os, and heterogenous placental signal with focal uterine bulge suggestive of placenta percreta (Fig. 1). Her laboratory reports was hemoglobin 10.4gm/dl, total leucocyte count 12,700/cu.mm, platelets 110,000/cu.mm, prothrombin time 14.2 s, INR 1.1, blood urea 56.3 mg/dl, creatinine 1.7 mg/dl, total bilirubin 5.6 mg/dl, and SGOT/SGPT 27.7/7 U/L. She was planned for a hysterectomy after uterine artery embolization. Digital subtraction angiography revealed hypertrophied and tortuous uterine arteries and multiple collaterals from other internal iliac artery branches, the left side being the dominant supplier. More than 90% devascularization was achieved with N-butyl cyanoacrylate, polyvinyl alcohol, and gel foam slurry embolization.

* Correspondence: drraj76pmch@gmail.com

¹All India Institute of Medical Science, Patna, Patna, India
Full list of author information is available at the end of the article

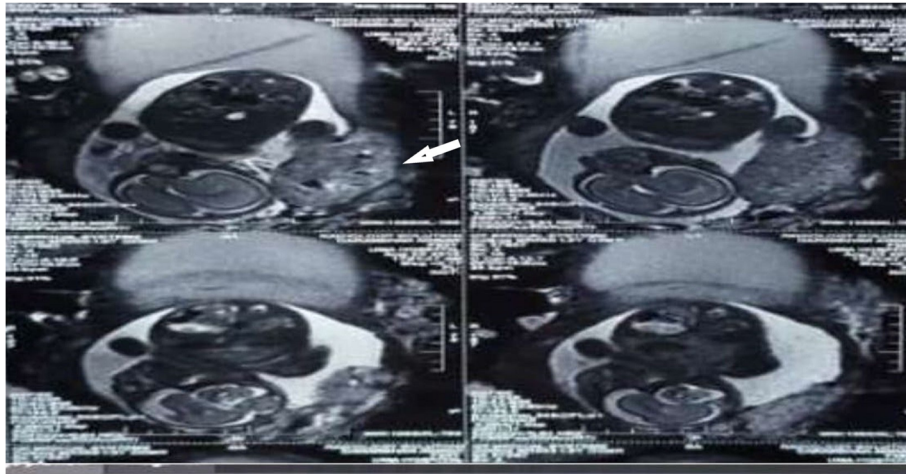


Fig. 1 MR image showing the placenta infiltrating the anterior lower uterine segment

Adequate blood and blood product were arranged, informed written consent was obtained.

The patient was shifted to the operative room; monitors were applied, and baseline parameters were recorded. The epidural catheter was placed at L2-3 space, and the test dose was negative. The patient was induced after adequate preoxygenation with fentanyl 2mcg/kg, propofol 2 mg/kg, and succinylcholine 1.5 mg/kg. After confirming adequate ventilation, the trachea was intubated with 7.5 mm internal diameter cuffed tube. Anesthesia was maintained with air, oxygen, and isoflurane and an intermittent bolus of inj. atracurium and fentanyl. Ultrasound-guided right internal jugular vein cannulation and left radial artery were cannulated. Laparotomy was done, and the fetus was delivered by hysterotomy. Hysterectomy was done, and hemostasis was achieved. Placenta had extended towards the bladder, so the bladder had to be dissected carefully from the uterus. The urologist help was taken for separation of the bladder. Bladder separation causes major bleeding, and the total operative time was 3 h and 45 min. Systolic blood pressure falls below 90 mm of Hg during it, so she was started on noradrenaline infusion @5µgm/min and gradually stopped in 2 h. The total amount of blood loss was 1500 ml. Blood loss was replaced with a crystalloid of 3000 ml, 3 units of PRBC, 4 units of FFP, and 4 units of platelets. Intraoperative urine output was 800 ml. The trachea was extubated after adequate reversal from muscle relaxation. She was shifted to the intensive care unit for vital monitoring. Intraoperative arterial blood gas analysis report was normal except the hemoglobin was 8.4gm%. She received 1 unit of PRBC. Postoperative pain was managed with patient-controlled epidural analgesia with 0.125% bupivacaine and fentanyl 2 µgm/ml @5 ml/h with 5 ml demand dose and 15 min lockout interval for 72 h along with paracetamol 1 gm 8

hourly. After 24 h, enoxaparin 40 mg was started for thromboprophylaxis. Her creatinine increased from 1.7 to 2.5 mg/dl on a postoperative day 1 and become normal on the fourth postoperative day. The patient was shifted to the ward on the fifth postoperative day. The patient was discharged from the ward in a stable condition.

Discussion

Obstetric hemorrhage accounts for 25% to 30% of all maternal deaths worldwide. Placenta previa is one of the common causes of antepartum hemorrhage. Placenta percreta is the most severe form of placenta invasion outside the uterus. Placenta accreta and increta are supplied by the uterine artery, so clamping of the uterine artery can stop the bleeding. But in the case of placenta percreta, the formation of neoblood vessels may lead to massive bleeding during the surgical period. In our case, major bleeding happens during the separation of the placenta from the bladder (Reitman et al., 2011). Placenta percreta can lead to bladder injury, bowel injury, major bleeding with severe coagulopathy, and peripartum hysterectomy. Ultrasonography and Doppler are sufficient for the diagnosis of abnormal placenta implantation. MRI is accurate in diagnosing the placenta percreta and posterior placenta, and it has a sensitivity of 80–88% and a specificity of 60–100% in the diagnosis of placenta percreta (Palacios Jaraquemada & Bruno, 2005). The maternal death rate due to placenta percreta is 9.5% (Mallawaarachchi & Pallemulla, 2018). Different endovascular procedures that may reduce blood loss are internal iliac artery occlusion, uterine artery occlusion/embolization, common iliac artery occlusion, and aortic occlusion. Uterine artery embolization is safe before the surgical intervention to reduce blood loss as in this case. The author has reported that prophylactic transcatheter

embolization was safe and effective for reducing intraoperative hemorrhage from removing an invasive placenta in patients with abnormal placentation (Huang et al., 2018). The combined bilateral internal iliac artery balloon occlusion and uterine artery embolization for cesarean delivery may be an effective strategy to control intraoperative blood loss and preserve the uterus in patients with invasive placenta undergoing cesarean delivery. The authors have reported a case series of five patients where they have successfully managed a placenta percreta by using resuscitative endovascular balloon occlusion of the aorta in obstetric surgery (Stubbs et al., 2020). In a recent study on 57 patients of placenta previa with suspicion of placenta accreta to use intraoperative abdominal aortic balloon occlusion during cesarean section, their data suggested that the severity of aberrant placental position does not affect the blood loss during a cesarean section with use of intraoperative abdominal aortic balloon occlusion (Li et al., 2020). Other authors even successfully managed a case of triplet gestation with placenta percreta for cesarean section under general anesthesia (Ismail & Azizullah, 2019). The author has managed successfully a case of placenta percreta under general anesthesia and given blood and blood product transfusion on the guidance of rotational thromboelastography (Hunter & Kleiman, 1996).

General anesthesia is of choice of anesthesia for patients in these types of cases. Epidural catheter was used in this case only as analgesia in the postoperative period due to major blood loss during the intraoperative period. General anesthesia maintains hemodynamic stability in the event of a massive hemorrhage. Combined spinal epidural anesthesia is another option in this case, but major blood loss may lead to hypotension. Another challenge with this case was her renal function was not normal. It has been reported that contrast used uterine artery embolization may cause acute renal failure (Parva et al., 2010).

Conclusions

We conclude that proper preoperative planning and good communication with the multidisciplinary approach will make a better outcome in these types of cases.

Abbreviations

LSCS: Lower segment cesarean section; PRBC: Packed red blood cell; FFP: Fresh frozen plasma; MRI: Magnetic resonance imaging

Acknowledgements

None

Authors' contributions

RK: manuscript preparation, concept. NS: manuscript review. SN: manuscript editing. RK: literature search. The authors read and approved the final manuscript.

Funding

Nil

Availability of data and materials

Not applicable

Declarations

Ethical approval and consent to participate

Ethics approval is not required, and consent was taken.

Consent for publication

Written informed consent was taken from the patient parent for the publication of this case.

Competing interests

The authors declare that they have no competing interests.

Author details

¹All India Institute of Medical Science, Patna, Patna, India. ²Paras Hospital, Patna, Patna, India.

Received: 8 March 2021 Accepted: 10 December 2021

Published online: 04 February 2022

References

- Huang KL, Tsai CC, Fu HC (2018) Prophylactic transcatheter arterial embolization helps intraoperative hemorrhagic control for removing invasive placenta. *J Clin Med* 7:460. [10.3390%2Fjcm7110460](https://doi.org/10.3390%2Fjcm7110460)
- Hunter T, Kleiman S (1996) Anaesthesia for caesarean hysterectomy in a patient with a preoperative diagnosis of placenta percreta with invasion of the urinary bladder. *Can J Anaesth* 43(3):246–248. <https://doi.org/10.1007/BF03011743>
- Ismail SA, Azizullah A (2019) Management of parturient with triplet pregnancy and placenta percreta: importance of multi-disciplinary approach. *J Obstet Anaesth Crit Care* 9(1):43–45. https://doi.org/10.4103/joacc.JOACC_60_18
- Li P, Liu X, Li X, Wei X, Liao J (2020) Clinical outcomes and anesthetic management of pregnancies with placenta previa and suspicion for placenta accreta undergoing intraoperative abdominal aortic balloon occlusion during cesarean section. *BMC Anesthesiol* 20:133. <https://doi.org/10.1186/s12871-020-01040-8>
- Mallawaarachchi RP, Pallemulla R (2018) Perioperative anesthetic management of a pregnant mother with placenta percreta. *J Obstet Anaesth Crit Care* 8(2): 99–101. https://doi.org/10.4103/joacc.JOACC_8_18
- Palacios Jaraquemada JM, Bruno CH (2005) Magnetic resonance imaging in 300 cases of placenta accreta: surgical correlation of new findings. *Acta Obstet Gynecol Scand* 84(8):716e724–716e724. <https://doi.org/10.1111/j.0001-6349.2005.00832.x>
- Parva M, Chamchad D, Keegan J, Gerson A, Horrow J (2010) Placenta percreta with invasion of the bladder wall: management with a multi-disciplinary approach. *J Clin Anesth* 22:209–212. <https://doi.org/10.1016/j.jclinane.2009.03.018>
- Reitman E, Devine PC, Laifer-Narin SL, Flood P (2011) Case scenario: perioperative management of a multigravida at 34-week gestation diagnosed with abnormal placentation. *Anesthesiology* 115(4):852–857. <https://doi.org/10.1097/ALN.0b013e31822ea436>
- Say L, Chou D, Gemmill A (2014) Global causes of maternal death: a WHO systematic analysis. *Lancet Glob. Health* 2(6):323–333. [https://doi.org/10.1016/S2214-109X\(14\)70227-X](https://doi.org/10.1016/S2214-109X(14)70227-X)
- Stubbs MK, Wellbeloved MA, Vally JC (2020) The management of patients with placenta percreta: a case series comparing the use of resuscitative endovascular balloon occlusion of the aorta with aortic cross clamp. *Indian J Anaesth* 64:520–523. <https://doi.org/10.4103/ija>

Publisher's Note

Springer Nature remains neutral with regard to jurisdictional claims in published maps and institutional affiliations.