

CASE REPORT

Open Access



Deep bradycardia after sugammadex: is it due to anaphylaxis or by any other unknown mechanism(s) of sugammadex?

Fulya Yilmaz^{1*}  and Koray Bas²

Abstract

Background: Sugammadex is a γ -cyclodextrin containing 8-thiopropionate side chains, which selectively binds to nondepolarizing aminosteroid neuromuscular blocking agents. Here, we report a case who developed deep bradycardia after administration of sugammadex.

Case presentation: A 38-year-old-man was scheduled for laparoscopic right hemicolectomy. Besides history of light smoking, he had no other medical/surgical history that included any allergic reactions. At the end of the operation, 200 mg sugammadex was administered to antagonize residual neuromuscular blockade. One minute after the administration of sugammadex, the patient had deep bradycardia (25 beat min^{-1}) and his systolic blood pressure fell below a measurable level. The patient's blood pressure was restored to 95/55 mmHg and heart rate 110 beats min^{-1} with the administration of a total dose of ephedrine 10 mg, atropine sulfate 0.5 mg, 0.9% saline 1 L, and 6% hydroxyethylated starch 500 mL over 15 min. Then, he was extubated uneventfully and transferred to the intensive care unit for closer monitoring.

Conclusions: According to the current literature as well as the case we presented here, we suggest that physicians who use sugammadex especially in endoscopic/laparoscopic procedures using CO_2 should be aware of the possibility of sudden bradycardia and/or cardiac arrest.

Keywords: Sugammadex, Deep bradycardia, Anaphylaxis, Laparoscopic surgery

Background

Sugammadex is a γ -cyclodextrin containing 8 thiopropionate side chains, which selectively binds to nondepolarizing aminosteroid neuromuscular blocking agents, forming a host-guest complex by directly encapsulating the rocuronium (Mineoka et al., 2016; Yamaoka et al., 2017; Ho et al., 2016; Min et al., 2018). It supplies rapid, safe, predictable, and urgent reversal of aminosteroid neuromuscular blocking agents especially rocuronium and is considered as a well-tolerated drug (Mineoka et al., 2016; Ho et al., 2016; Min et al., 2018; Menedez-

Ozcoidi et al., 2011). In recent years, sugammadex has been used more frequently in clinical practice with the changes in anesthesia management. By the frequent use of sugammadex in clinical practice, the adverse reaction(s) of sugammadex, sudden bradycardia and/or cardiac arrest, have been encountered often and the number of publications about this adverse reaction(s) has been increased (Ho et al., 2016). Here, we report a case who developed deep bradycardia after administration of sugammadex.

Case presentation

Written informed consent was obtained from the patient for hid anonymized information to be published in this case report. A 38-year-old-man (weight 77 kg, height 170 cm) with a diagnosis of colonic adenoma with high-

* Correspondence: fulya.dr@gmail.com

¹University of Health Sciences Izmir Bozyaka Training and Research Hospital Department of Anaesthesiology and Reanimation, Saim Çıkrıkçı Caddesi No: 59 Karabağlar, Izmir, Turkey
Full list of author information is available at the end of the article

grade dysplasia was scheduled for laparoscopic right hemicolectomy at the University of Health Sciences Izmir Bozyaka Training and Research Hospital. Besides history of light smoking, he had no other medical or surgical history. He had also no history of allergies. After insertion of an epidural catheter, for postoperative analgesia, at L₃₋₄ level and confirmed negative aspiration for blood and cerebro-spinal fluid, 2 mL lidocaine 2% (40 mg) was injected via catheter over 30 s. The patient's baseline blood pressure was 129/70 mmHg, and heart rate was 80 beats min⁻¹. After the epidural catheter was tested, general anesthesia was induced with propofol 200 mg, rocuronium 50 mg, and remifentanil 0.2 µg kg⁻¹ min⁻¹, followed by tracheal intubation in the usual fashion by a spiral endotracheal tube, size of 8 mm. Anesthesia was maintained with 6% desflurane in 45% oxygen and air, remifentanil 0.03 µg kg⁻¹ min⁻¹, and intermittent epidural doses of 0.25% bupivacaine. A central venous catheter was placed to the right internal jugular vein by ultrasound guidance, and arterial catheterization was applied to the left radial artery. Cefazoline 1 g was administered as preoperative antibiotic prophylaxis. The surgery was completed uneventfully. Half an hour before ending of surgery, a total dose of 1 mg morphine in 5 mL was administered epidurally for postoperative analgesia and ranitidine hydrochloride (50 mg) for peptic ulcer prophylaxes. At the end of the operation, 200 mg sugammadex (corresponding to 2.5 mg kg⁻¹) was administered to antagonize residual neuromuscular blockade. One minute after the administration of sugammadex, while the patient was still on mechanic ventilation and unconsciousness, he had deep bradycardia (25 beat min⁻¹) and his systolic blood pressure fell below the measurable level (Figs. 1 and 2). Intravenous fluid resuscitation was begun, and ephedrine 10 mg and atropine sulfate 0.5 mg were administered. Subsequently, ST depression and ventricular premature contraction

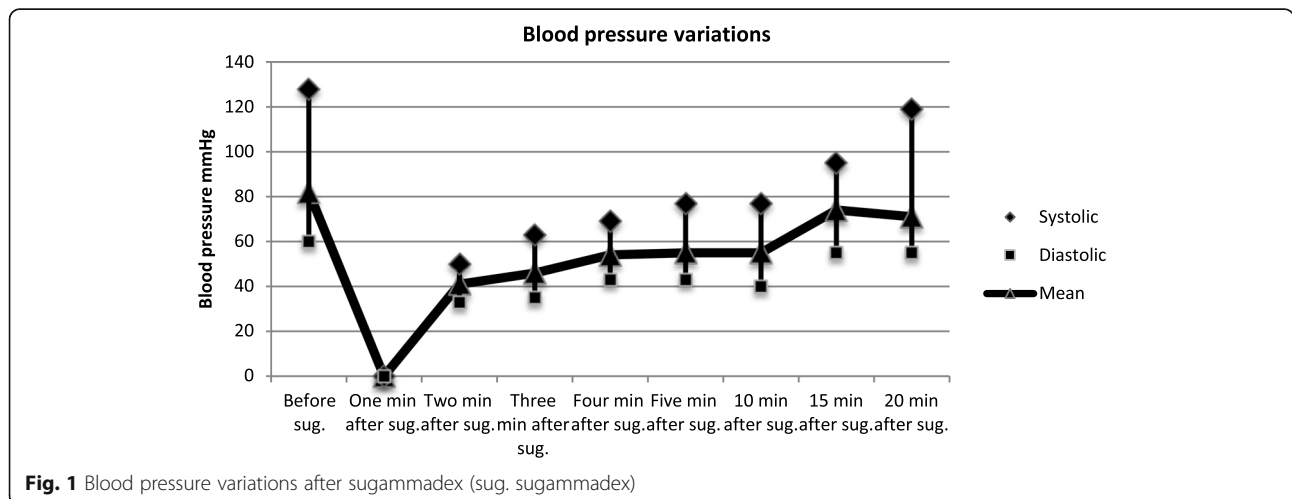
were observed in the electrocardiogram. Suspecting of a drug-induced anaphylaxis, intravenous methylprednisolone (100 mg) was also administered. He was ventilated on volume control ventilation mode with 100% oxygen. The patient's blood pressure was restored to 95/55 mmHg and heart rate 110 beats min⁻¹ with the administration of a total dose of ephedrine 10 mg, atropine sulfate 0.5 mg, 1 L 0.9% saline, and 6% hydroxyethylated starch 500 mL over 15 min. Then, the patient was extubated and transferred to the intensive care unit. He was discharged from the ICU on 1st and from the hospital on 7th postoperative day uneventfully (Fig. 3).

Discussion

In our patient, a deep bradycardia occurred following a single intravenous dose of 200 mg sugammadex (corresponding to 2.5 mg kg⁻¹) right after a laparoscopic right hemicolectomy.

The adverse reaction(s) of sugammadex, sudden bradycardia and/or cardiac arrest, have been encountered often by the frequent use of sugammadex in clinical practice. While this adverse reaction was explained as a result of anaphylaxis in previous publications; nowadays, recent publications and the producers reported that this can occur with unknown mechanisms without evidence of anaphylaxis. Interestingly, endoscopic/laparoscopic procedures using CO₂ may contribute to this adverse event when sugammadex is used for reversal of neuromuscular blockade at the end of the surgery (Bhavani, 2018).

Rocuronium, a nondepolarizing aminosteroid neuromuscular blocker, is commonly blamed for the perioperative anaphylaxis (Yamaoka et al., 2017); sugammadex itself can also trigger anaphylactic reactions (Mineoka et al., 2016; Obara et al., 2018); and surprisingly, rocuronium-sugammadex complex can become the potential allergen (Mineoka et al., 2016; Yamaoka et al., 2017; Ho et al.,



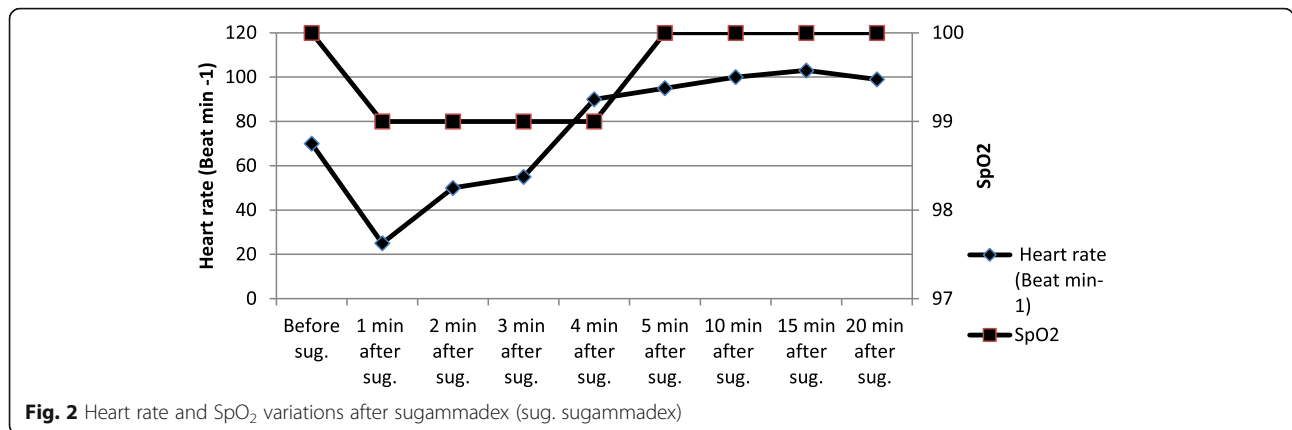


Fig. 2 Heart rate and SpO₂ variations after sugammadex (sug. sugammadex)

2016). In contrast, rocuronium-induced anaphylaxis was successfully treated with sugammadex (Mineoka et al., 2016; Menedez-Ozcoidi et al., 2011).

So many authors, Hotta et al. (Mineoka et al., 2016), Ozcoidi et al. (Menedez-Ozcoidi et al., 2011), Ho et al. (Ho et al., 2016), Yamaoka et al. (Yamaoka et al., 2017), Tokuwaka et al. (Tokuwaka et al., 2013), and Horiuchi et al. (Horiuchi et al., 2018), reported anaphylaxis that leads to hypotension and/or bradycardia by sugammadex or rocuronium-sugammadex complex. They revealed anaphylaxis with some laboratory tests as serum mast cell tryptase level, skin tests, basophil activation test, and drug-induced lymphocyte stimulation test. Obara et al. (Obara et al., 2018) reported the first case of sugammadex (2.5 mg kg⁻¹)-induced severe anaphylaxis causing cardiac arrest.

Ho et al. (Ho et al., 2016) reported a case (50-year-old, 95-kg man, laparoscopic appendectomy) who developed unrecordable blood pressure and bradycardia (40–50 beat min⁻¹) after sugammadex administration due to allergy to rocuronium-sugammadex complex. They reported some clinical and laboratory evidences of allergic reactions such as wheeze, swelling, erythema, and increased serum mast cell tryptase levels. Also, our case was operated by laparoscopic technique and we

encountered deep bradycardia after sugammadex administration.

On the other hand, Bhavani (Bhavani, 2018) reported two cases of significant bradycardia and asystole after sugammadex administration in patients undergoing gastrointestinal endoscopic procedures with the use of carbon dioxide for bowel insufflation. These cases had no clinical or laboratory evidence of allergic reactions. Although the safety of CO₂ use in endoscopic procedures is well established, they emphasize that further studies are needed to examine the safety of sugammadex in endoscopic procedures using CO₂. Maybe laparoscopic surgery was the additional risk factor except allergic reaction in the case that Ho et al. (Ho et al., 2016) reported.

As it is clearly stated like “Cases of marked bradycardia, some of which have resulted in cardiac arrest, have been observed within minutes after the administration of sugammadex” in the sugammadex data sheet (Bridion, 2018). We observed deep bradycardia (25 beat min⁻¹), unmeasurable blood pressure, and a sudden decrease in PO₂ level which was considered as a sign of bronchoconstriction in our patient. We applied anaphylaxis treatment and managed the patient successfully.

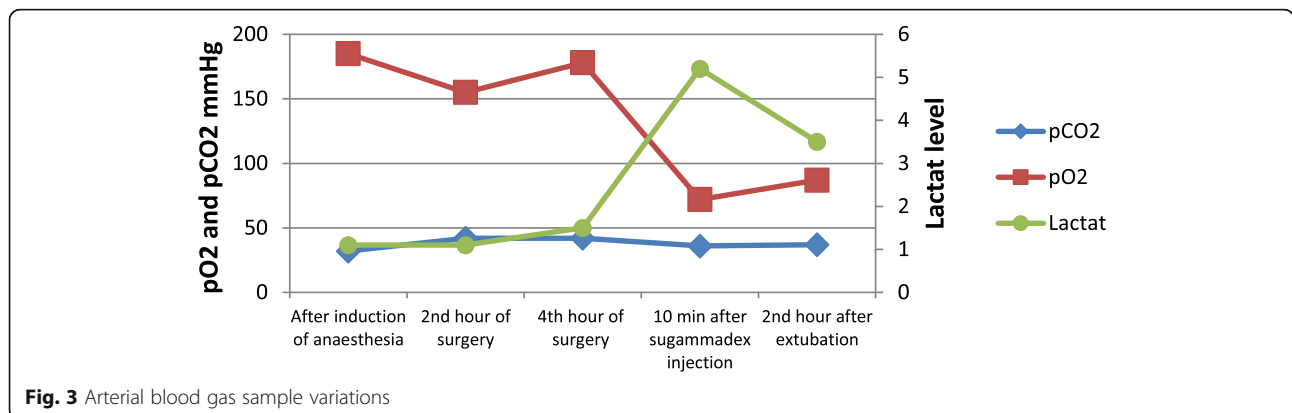


Fig. 3 Arterial blood gas sample variations

Our limitation in this report is that we could not be able to evaluate the tryptase level to demonstrate it was an anaphylactic reaction. The deep bradycardia we encountered may be due to unknown mechanism(s) after sugammadex application as the producing company highlighted. Furthermore, we do not know whether laparoscopic surgery was another risk factor in our case as mentioned earlier by Bhavani (Bhavani, 2018).

Conclusions

According to the current literature as well as the case we presented here, we suggest that physicians who use sugammadex especially in endoscopic/laparoscopic procedures using CO₂ should be aware of the possibility of sudden bradycardia and/or cardiac arrest. Further studies are needed to approve and explain the mechanism(s) of these reverse events if they were due to sugammadex.

Abbreviations

CO₂: Carbon dioxide; PO₂: Partial oxygen pressure

Acknowledgements

This case report was presented as an oral presentation in 22st of International Intensive Care Symposium Hilton Bomonti Hotel & Conference Center, 3–4 May 2019.

Authors' contributions

FY and KB have reviewed the available literature, prepared the primary manuscript, reviewed and edited the final manuscript, and approved the final manuscript.

Funding

None

Availability of data and materials

The datasets used and/or analyzed during the current study are available from the corresponding author on reasonable request.

Ethics approval and consent to participate

Ethical approval is not required for the publication of isolated case reports. The patient was informed about the procedure, and a written informed consent was obtained.

Consent for publication

Written permission/consent of the patient for the purpose of publication in an educational medical journal was obtained from the patient.

Competing interests

The authors declare that they have no competing interests.

Author details

¹University of Health Sciences Izmir Bozyaka Training and Research Hospital Department of Anaesthesiology and Reanimation, Saim Çıkırıkçı Caddesi No: 59 Karabağlar, Izmir, Turkey. ²University of Health Sciences Izmir Bozyaka Training and Research Hospital Department of General Surgery, Saim Çıkırıkçı Caddesi No: 59 Karabağlar, Izmir, Turkey.

Received: 15 May 2020 Accepted: 3 September 2020

Published online: 16 September 2020

References

- Bhavani SS (2018) Severe bradycardia and asystole after sugammadex. *Bri J Anaesthesia* 121(1):95–96
- Bridion: highlights of prescribing information. Available from https://www.merck.com/product/usa/pi_circulars/b/bridion/bridion_pi.pdf (accessed 6 Feb 2018).

- Ho G, Clarke RC, Sadleir PHM, Platt PR (2016) The first case report of anaphylaxis caused by the inclusion complex of rocuronium and sugammadex. *A A Case Rep* 7(9):190–192
- Horiuchi T, Yokohama A, Orihara M, Tomita Y, Tomioka A, Yoshida N, Takahashi K, Saito S, Takazawa T (2018) Usefulness of basophil activation tests for diagnosis of sugammadex-induced anaphylaxis. *Anesth Analg*. 126(5):1509–1516
- Mendez-Ozcoidi LM, Ortiz-Gomez RO, Olaguibel-Ribero JMO, Salvador-Bravo MJ (2011) Allergy to low dose sugammadex. *Anaesthesia* 66:217–219
- Min KC, Woo T, Assaid C, McCrea J, Gurner DM, Sisk CM, Adkinson F, Herring WJ (2018) Incidence of hypersensitivity and anaphylaxis with sugammadex. *J Clin Anesth*. 47:67–73
- Mineoka HE, RT MK, Taura M, Nakagawa Y, Kanehisa F, Tashima S, Katoh N (2016) Anaphylaxis caused by g-cyclodextrin in sugammadex. *Allergol Int* 65:356–358
- Obara S, Kurosawa S, Honda J, Oishi R, Iseki Y, Murakawa M (2018) Cardiac arrest following anaphylaxis induced by sugammadex in a regional hospital. *J Clin Anesth* 44:62–63
- Tokuwaka J, Takahashi S, Tanaka M (2013) Anaphylaxis after sugammadex administration. *Can J Anesth* 60:733–734
- Yamaoka M, Deguch M, Ninomiya K, Kurasako T, Matsumoto M (2017) A suspected case of rocuronium–sugammadex complex-induced anaphylactic shock after cesarean section. *J Anesth* 31:148–151

Publisher's Note

Springer Nature remains neutral with regard to jurisdictional claims in published maps and institutional affiliations.

Submit your manuscript to a SpringerOpen[®] journal and benefit from:

- Convenient online submission
- Rigorous peer review
- Open access: articles freely available online
- High visibility within the field
- Retaining the copyright to your article

Submit your next manuscript at ► [springeropen.com](https://www.springeropen.com)