


LETTER TO THE EDITOR

Open Access



Ultrasound-guided combined interscalene and superficial cervical plexus blocks for anesthesia management during clavicle fracture surgery

Ahmet Kacıroglu¹, Muhammet Ahmet Karakaya², Ali Ahiskalioglu³, Bahadır Ciftci^{4,5,6*} , Mursel Ekinci⁴ and Ahmet Murat Yayik⁷

To the Editor,

Fractures of the clavicle constitute 2.6–4% of all fractures in adult patients. The most frequent injury mechanism is a direct trauma on the shoulder. These fractures are mainly treated surgically (Kihlstrom et al. 2017). The cervical and brachial plexus innervate the clavicular region (Tran et al. 2013). Thus, interscalene brachial plexus block (IBPB) and superficial cervical plexus block (SCPB) may be used for pain management following clavicular surgery. Herein, we aimed to report our ultrasound (US)-guided IBPB and SCPB combination experiences for anesthetic management during clavicular surgery.

Sixteen patients who underwent clavicular surgery were analyzed retrospectively. US-guided combined IBPB and SCPB were performed to the patients. 7.5 ml of 2% lidocaine and 7.5 ml of 0.5% bupivacaine for IBPB and 5 ml of 2% lidocaine and 5 ml of 0.5% bupivacaine for SCPB were injected using a 7–12-MHz linear probe via in-plane technique (Fig. 1). Age, sex, additional sedation requirement, recovery time of motor block, VAS scores, postoperative analgesic use, adverse events, complications, and the patients who needed general anesthesia were recorded from the routine form of operation. The patients' characteristics and operational data are shown in Table 1. Fracture localization was lateral in six cases, midshaft in eight cases, and medial in two cases. General anesthesia was performed in one patient. Additional

sedoanalgesia was performed for four patients. No additional sedoanalgesia was performed in six cases with lateral fracture. Sedoanalgesia was performed in three patients with midshaft fracture. One case with medial fracture underwent general anesthesia, and the other one was performed under sedoanalgesia.

Discussion

The sensorineural innervation of the clavicle is a complex issue. The osseous part is mainly innervated by long thoracic, subclavian, supraclavicular, and suprascapular nerves that originated from C3–5 roots. Since these nerves are originated from the brachial plexus, they may be blocked between the scalene muscles. The skin is innervated from SCP which originated from anterior rami of C1–4 nerve root. The SCP leaves from the lateral part of the upper 1/3 sternocleidomastoid muscle (Tran et al. 2013; Shanthanna 2014). IBPB and SCPB may be used for pain management following clavicular surgery. In the literature, IBPB and SCPB were reported for anesthesia management in a few number of cases and retrospective studies (Vandepitte et al. 2014; Dillane et al. 2014; Reverdy 2015).

IBPB and SCPB may cause complications such as phrenic nerve palsy, vocal cord paralysis, pneumothorax, and spinal cord injury. There were no block-related complications in our cases.

* Correspondence: bciftci@medipol.edu.tr; baha_cftci@hotmail.com

⁴Department of Anesthesiology and Reanimation, Istanbul Medipol University Hospital Complex, Bagcilar, Istanbul 34040, Turkey

⁵Department of Anesthesiology and Reanimation, Regional Training Hospital, Erzurum, Turkey

Full list of author information is available at the end of the article

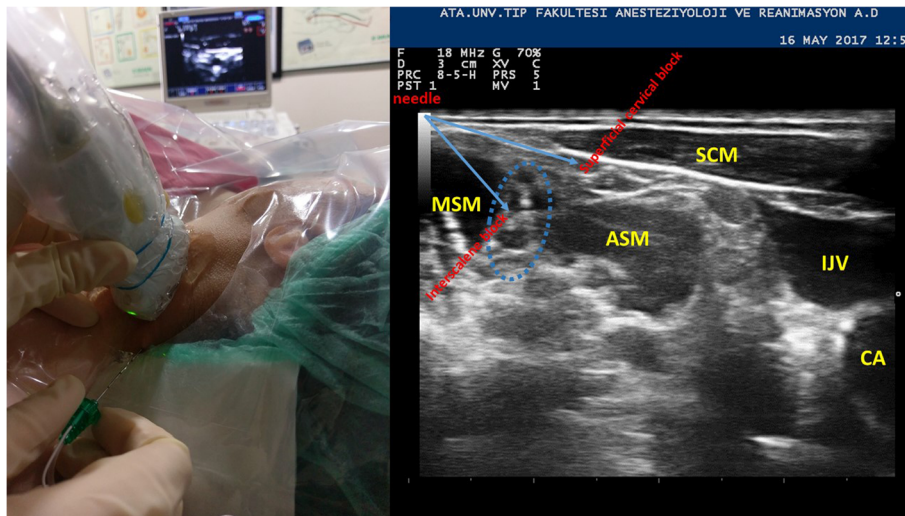


Fig. 1 Patient, probe, and ultrasound setup for block with sonographic anatomy of interscalene-superficial cervical block area. SCM sternocleidomastoid muscle, ASM anterior scalene muscle, MSM middle scalene muscle, IJV internal jugular vein, CA carotid artery

The patient who was administered general anesthesia had medial clavicular fracture case. One of the patients who received additional sedation had medial fracture case, and the other three had midshaft fracture. These results support that IBPB provides analgesia in proximal humerus, shoulder joint, and 2/3 lateral part of the clavicle. The adverse events such as nausea, vomiting, and itching occurred in those who were administered additional sedation/sedoanalgesia via opioid agents.

Table 1 The demographic and operational characteristics of the patients and adverse events

Age	44 ± 14
Weight (kg)	77 ± 11
Height (cm)	170 ± 8
Sex (M/F)	13/3
ASA class (I/II/III)	9/5/2
Duration of surgery (min)	80 ± 28
Duration of anesthesia (min)	116 ± 27
Fracture localization (lateral/midshaft/medial)	6/8/2
Recovery of motor block time (min)	213 ± 60
The need for analgesia for the first time (min) (VAS > 4)	259 ± 99
Continue with general anesthesia	1 (6.25%)
Additional sedoanalgesia	4 (25%)
Adverse events	
Nausea	4
Vomiting	1
Itching	3

Data are expressed as mean ± standard deviation or number (%)

The combination of US-guided IBPB and SCPB may be used for anesthesia during clavicular fracture surgery for patients having high risk rate for general anesthesia. Further studies may be needed in terms of this.

Abbreviations

IBPB: Interscalene brachial plexus block; SCPB: Superficial cervical plexus block; US: Ultrasound; VAS: Visual analog score

Acknowledgements

Not applicable

Authors' contributions

All of the writers contributed to the writing, literature scanning, and block performing. All authors read and approved the final manuscript.

Funding

Not applicable

Availability of data and materials

Not applicable

Ethics approval and consent to participate

Not applicable

Consent for publication

A written informed consent was obtained from the patients for publication.

Competing interests

The authors declare that they have no competing interests.

Author details

¹Department of Anesthesiology and Reanimation, Fatih Sultan Mehmet Training and Research Hospital, Istanbul, Turkey. ²Department of Anesthesiology and Reanimation, Koc University Hospital, Istanbul, Turkey. ³Department of Anesthesiology and Reanimation, Ataturk University School of Medicine, Erzurum, Turkey. ⁴Department of Anesthesiology and Reanimation, Istanbul Medipol University Hospital Complex, Bagcilar, Istanbul 34040, Turkey. ⁵Department of Anesthesiology and Reanimation, Regional Training Hospital, Erzurum, Turkey. ⁶Department of Anesthesiology and Reanimation, Istanbul Medipol University Hospital Complex, Bagcilar, 34040

Istanbul, Turkey. ⁷Department of Anesthesiology and Reanimation, Regional Training Hospital, Erzurum, Turkey.

Received: 8 May 2019 Accepted: 24 September 2019

Published online: 21 November 2019

References

- Dillane D, Ozelsel T, Gadbois K (2014) Anesthesia for clavicular fracture and surgery. *Reg Anesth Pain Med* 39(3):256
- Kihlstrom C, Moller M, Lonn K, Wolf O (2017) Clavicle fractures: epidemiology, classification and treatment of 2422 fractures in the Swedish Fracture Register; an observational study. *BMC Musculoskelet Disord* 18(1):82
- Reverdy F (2015) Combined interscalene-superficial cervical plexus block for clavicle surgery: an easy technique to avoid general anesthesia. *BJA* 115(eLetters supplement). https://doi.org/10.1093/bja/e1_12970
- Shanthanna H (2014) Ultrasound guided selective cervical nerve root block and superficial cervical plexus block for surgeries on the clavicle. *Indian J Anaesth* 58(3):327
- Tran DQ, Tiyaprasertkul W, Gonzalez AP (2013) Analgesia for clavicular fracture and surgery: a call for evidence. *Reg Anesth Pain Med* 38(6):539
- m Vandepitte C, Latmore M, O'Murchu E, Hadzic A, Van de Velde M, Nijs S (2014) Combined interscalene-superficial cervical plexus blocks for surgical repair of a clavicular fracture in a 15-week pregnant woman. *Int J Obstet Anesth* 23(2):194

Publisher's Note

Springer Nature remains neutral with regard to jurisdictional claims in published maps and institutional affiliations.

Submit your manuscript to a SpringerOpen[®] journal and benefit from:

- Convenient online submission
- Rigorous peer review
- Open access: articles freely available online
- High visibility within the field
- Retaining the copyright to your article

Submit your next manuscript at ► [springeropen.com](https://www.springeropen.com)
